A close-up photograph of a hand, focusing on the fingers. The skin on the fingers is severely affected by plaque psoriasis, showing thick, raised, scaly plaques with a yellowish-brown hue. The plaques are most prominent on the dorsal surfaces of the fingers and the base of the thumb. The background is a plain, light-colored surface.

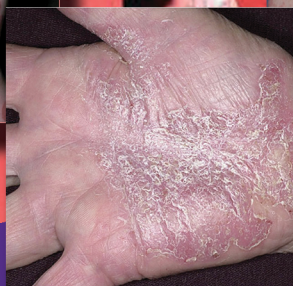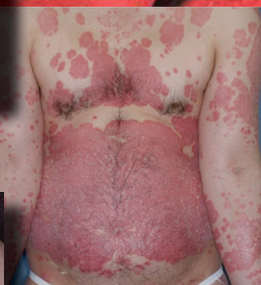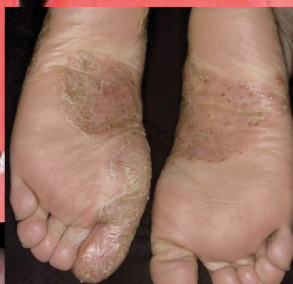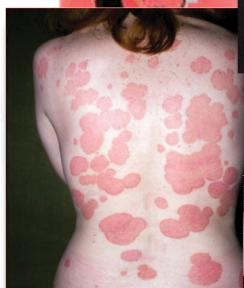You are Cordially Invited to an
Educational Presentation...

Patient Profiles in Moderate to Severe Plaque Psoriasis

A Case-Based Approach to Current Management

You are Cordially Invited to an Educational Presentation...

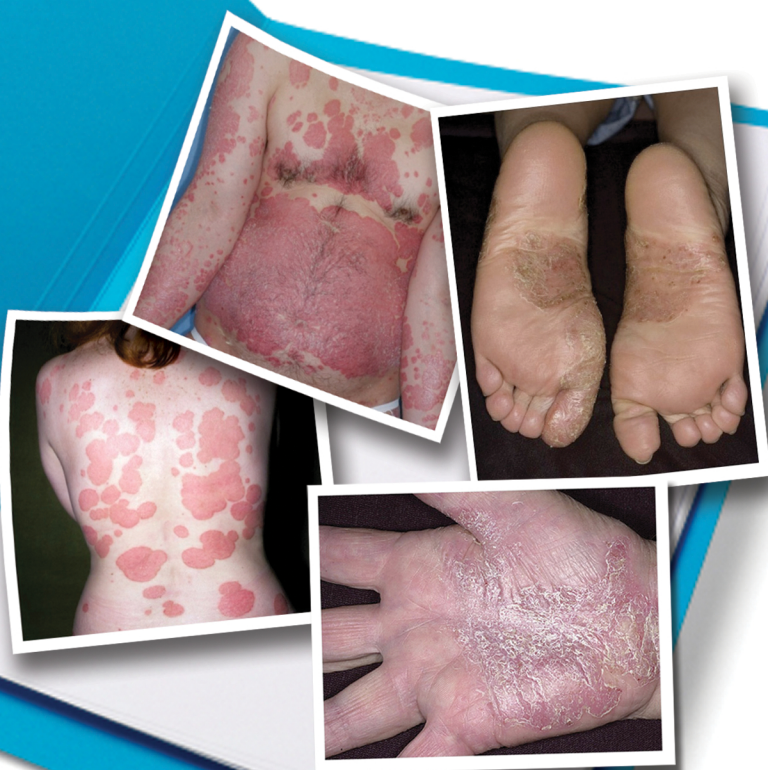Patient Profiles in Moderate to Severe Plaque Psoriasis



A Case-Based Approach to Current Management

You are Cordially Invited to
an Educational Presentation...

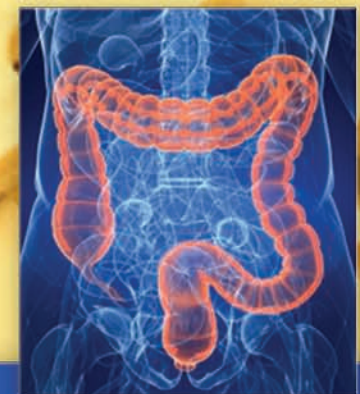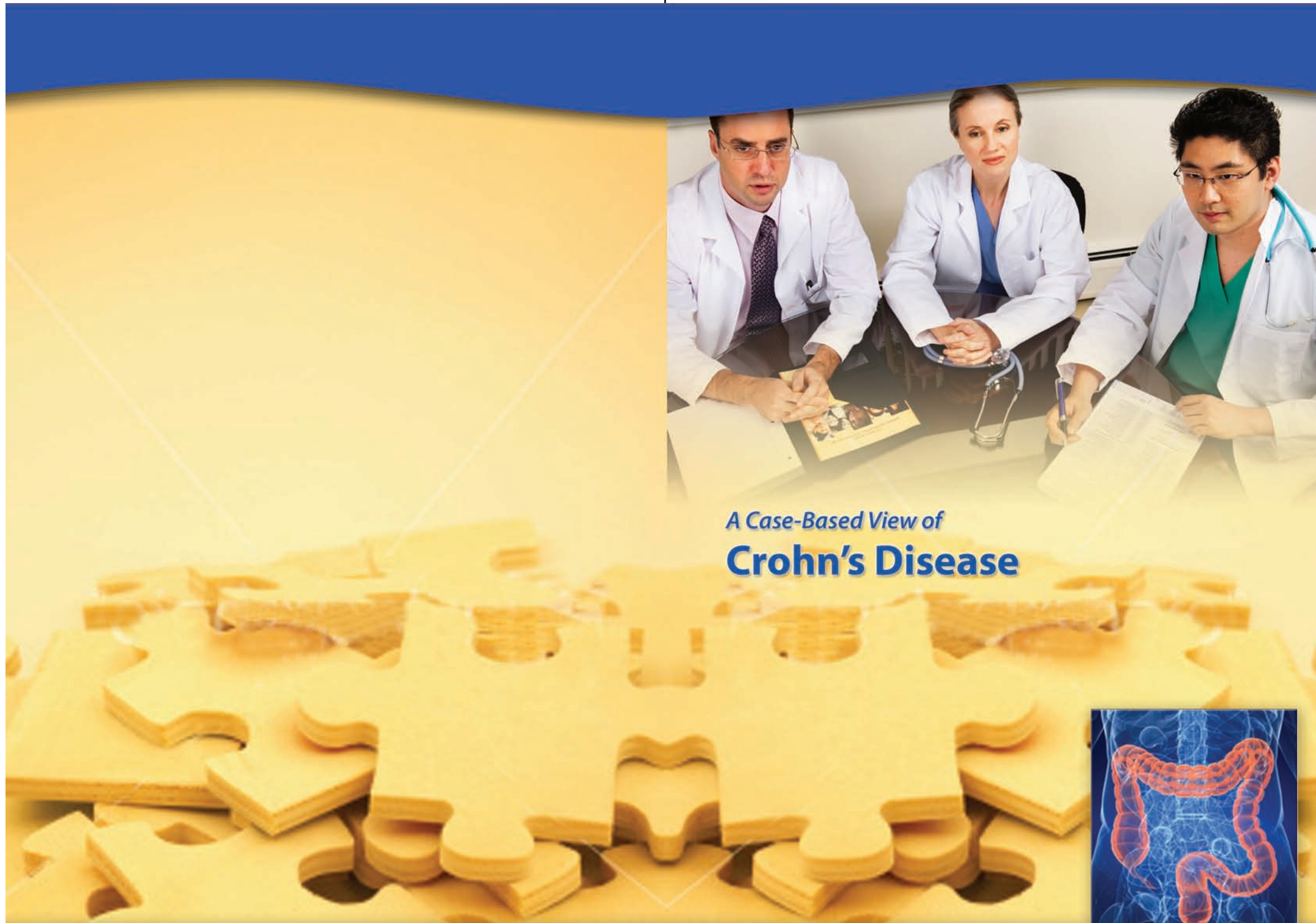
Patient Profiles in Moderate to Severe Plaque Psoriasis



A Case-Based Approach
to Current Management



A Case-Based View of
Crohn's Disease



Applying Current and Recent Data
to Individual Patient Care

You are Cordially Invited to a
Faculty Presentation



Clinical Case Conversations A Nurse's Perspective





You are
Cordially
Invited to a
**Faculty
Presentation**




Clinical Case Conversations A Nurse's Perspective



Centocor Ortho Biotech Inc.

A Case-Based View of Ulcerative Colitis



Applying Current and Recent
Data to Individual Patient Care