



REDUCE COSTS

Control documentation costs

Medical facilities see the value of investing in healthcare IT to improve the quality, safety and effectiveness of patient care. Still, they work to find the best means of accomplishing these goals while balancing cost and performance. In today's world of electronic health record adoption, transcription is often the vulnerable budgetary line item for reducing documentation costs. Shifting the burden of documentation onto clinicians, however, oftentimes results in a drop in productivity and, consequently, patient load.

Rather than eliminating transcription completely, Emdat maximizes the efficiencies of the dictation process and facilitates economical use of the transcriptionist. Clinicians and administrators that are empowered with tools that maximize their efficiency have just as vital an effect on revenue stream as technology that promises to eliminate costs, and can still provide quality care while fulfilling documentation responsibilities.



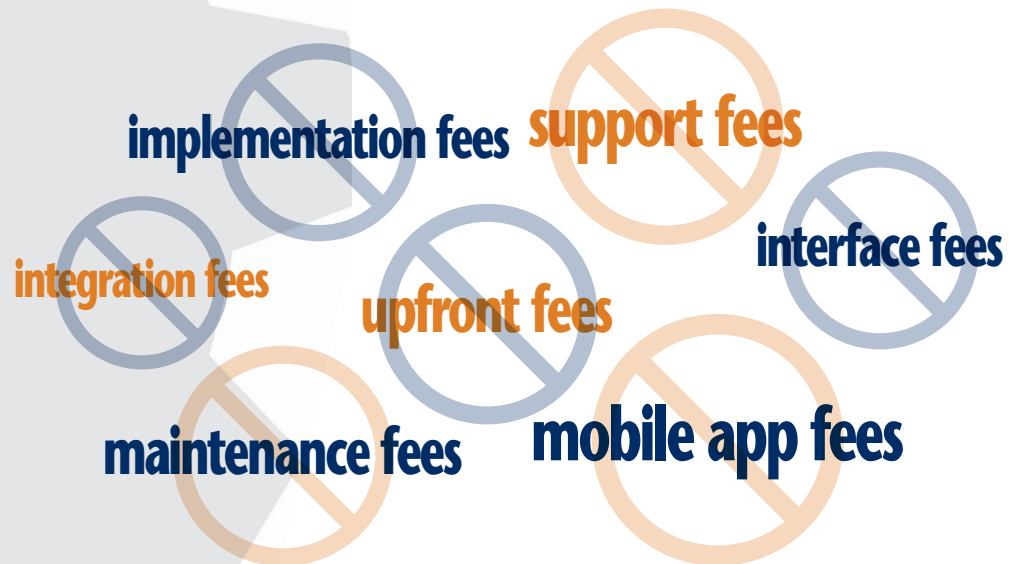
Savings are significant when 5-10 lines are shaved from thousands of transcription reports monthly. A total hard dollar cost reduction of 55% was realized the first year.



KATHY MAHAFFEY, COO
SOUTHERN ILLINOIS UNIVERSITY

Savings abound

Our price guarantee, no nickel and dimes



Innovative pricing model and exclusive functionality

Dramatically reduce line counts and transcription costs

- System-generated lines and features decrease the number of transcribed lines by as much as 35% and reduce costs by as much as 50%
- **Print Templates** — system-generated fixed content such as demographic field labels, letterhead information, carbon copy information, dates, headers, footers— eliminate the need for manual formatting and typing and are available at no cost
- **Qualified Text** — editable content automatically populated into transcriptions based on common text found within documentation — are billed at a significantly reduced rate, nearly 50% in savings
- Speech Recognition further decreases cost by requiring document editing rather than transcription, saving up to 20%
- Powerful capacity to control costs using an unlimited number of custom print, document and dictation templates that minimize transcription

XYZ MEDICAL FACILITY

AORTIC ANEURYSM SCREENING

Patient Name: John Doe Age: 45 Date of Birth: August 28, 1958
 Patient ID: 123456 Location: Chicago Gender: Male
 Dictating Physician: Frank Smith, M.D. Test Date: January 25, 2003

I had the opportunity to see your patient John Doe for consultation on January 25, 2003. Below are my findings for his Aortic Aneurysm Screening.

Indications:
 Men age 65 or older.
 Women age 65 or older with cardiovascular risk factors.
 Family history of aortic and peripheral vascular aneurysmal disease.

Examination Protocol:
 Transverse images of proximal (near diaphragm), mid and distal aorta.
 Longitudinal images with AP measurements (outer wall to outer wall) of proximal and distal aorta.

Aorta Measurements:
 Proximal: 2.1 cm
 Mid: 2.7 cm
 Distal: 2.9 cm

Interpretation: Abdominal aortic ultrasound was performed with attention to the mid and distal aorta. There is very small dilatation of the distal aorta. These findings are repeat examination with sonography is recommended.

Recommendations: Clinical correlation and repeat examination is recommended.

This paragraph is a fixed paragraph that a client can request at the end of every examination.

DD: January 25, 2003
 DT: January 26, 2003

Frank Smith, M.D.
 Professor of Cardiology

TID: 1245342

AT 11¢ PER LINE
\$2.42
 OTHER COMPANIES

XYZ MEDICAL FACILITY

AORTIC ANEURYSM SCREENING

Patient Name: John Doe **Age:** 45 **Date of Birth:** August 28, 1958
Patient ID: 123456 **Location:** Chicago **Gender:** Male
Dictating Physician: Frank Smith, M.D. **Test Date:** January 21, 2003

I had the opportunity to see your patient John Doe for consultation on January 25, 2003. Below are my findings for his Aortic Aneurysm Screening.

Indications:
 Men age 65 or older.
 Women age 65 or older with cardiovascular risk factors.
 Family history of aortic and peripheral vascular aneurysmal disease.

Examination Protocol:
 Transverse images of proximal (near diaphragm), mid and distal aorta.
 Longitudinal images with AP measurements (outer wall to outer wall) of proximal, mid and distal aorta.

Aorta Measurements:
 Proximal: 2.1 cm
 Mid: 2.7 cm
 Distal: 2.9 cm

Interpretation: Abdominal aortic ultrasound was performed with attention to the mid and distal aorta. There is very small dilatation of the distal aorta. These findings are repeat examination with sonography is recommended.

Recommendations: Clinical correlation and repeat examination is recommended.

This paragraph is a fixed paragraph that a client can request at the end of every examination.

DD: January 25, 2003
 DT: January 26, 2003

Frank Smith, M.D.
 Professor of Cardiology

TID: 1245342

44% SAVINGS
\$1.68
 EMDAT