

# Implant Realities™



Volume 2 • 2009

Implant Realities

Volume 2 • 2009 • IR209

www.iti.org



**Implant Realities**

© December 2009  
Printed in USA  
IR 209

www.iti.org



**ITI Mission Statement:**

To promote and disseminate knowledge on all aspects of implant dentistry and dental tissue regeneration through research, development, and education to the benefit of the patient.

**Implant Realities, Volume 2, 2009**

**Publisher**

International Team for Implantology  
US Section

**Editorial Board**

Paul A. Fugazzotto, DDS  
progressiveperio@aol.com

Frank L. Higginbottom, DDS  
bottom@dallasesthetics.com

**Graphic Design**

Straumann USA, LLC

**Printing**

DS Graphics, Inc. – Lowell, MA

**Publisher**

*Implant Realities* is published biannually by the International Team for Implantology (ITI) US Section © 2009. All rights reserved. No parts of this journal may be reproduced without permission from the publisher. The opinions expressed in articles are those of the authors and not necessarily those of the publisher or the editors.

A free copy of *Implant Realities* is sent to each US section ITI member and fellow at the time of its publication. Additional copies are available at a cost of \$12.95 per copy. Contributing authors receive ten free copies of the issue of *Implant Realities* in which their article appears.



**Paul A. Fugazzotto, DDS**  
*Editor in Chief,*  
*Implant Realities*

Welcome to the “Congress Issue” of *Implant Realities*. As you know, the US ITI Congress was held on April 24th and 25th in Scottsdale, Arizona. Over 600 attendees participated, listening to numerous expert presentations and trading ideas with their colleagues.

As always, both the presentations and discussions among Congress attendees during the breaks were characterized by a desire to deliver reality based comprehensive care to patients.

This issue of *Implant Realities* begins with editorials from ITI Fellows from various branches of dentistry, in an effort to underscore the importance of comprehensive interdisciplinary therapy.

Many of the presenters from the US ITI Congress were generous enough to share synopses of their presentations with us, as you will see in the ensuing pages.

Sharing of knowledge and a concern for delivery of the most up to date care possible in order to address patient needs and desires, based upon unassailable research and meticulous clinical execution, are the hallmarks of the ITI.

Sincerely,

A handwritten signature in black ink, appearing to be 'Paul A. Fugazzotto'. The signature is fluid and stylized, with a long horizontal stroke at the beginning and a large, sweeping loop at the end.

**Paul A. Fugazzotto, DDS**  
*Editor in Chief, Implant Realities*

# Table of Contents

## Meet the ITI:

<b>ITI Fellow: Robert A. Levine, DDS</b>	<b>4</b>
<b>ITI Member: Harry Randel, DMD</b>	<b>6</b>

## Editorials:

<b>The Role of Oral and Maxillofacial Surgeons in Implant Dentistry</b>	<b>8</b>
John-Michael Stewart, DMD	
<b>The Importance of the Restorative Dentist in Delivering Comprehensive Patient Care</b>	<b>9</b>
Robert C. Vogel, DDS	
<b>The Role of the Periodontist in the Field of Dental Implants</b>	<b>10</b>
Jay R. Beagle, DDS, MSD	
<b>Why A Laboratory Technician is Important in Comprehensive Treatments</b>	<b>11</b>
Jeff Singler	
<b>The Importance of the Orthodontist in Delivering Comprehensive Care</b>	<b>12</b>
Frank Celenza, DDS	

## Surgical:

<b>Beyond Titanium; Where No Implant Has Gone Before!</b>	<b>14</b>
David L. Cochran, DDS, PhD	
<b>Tissue Level Versus Bone Level; Is There a Difference?</b>	<b>16</b>
Jay R. Beagle, DDS, MSD	
<b>The Replacement of Hopeless Teeth in the Esthetic Zone with Dental Implants – A Decision-Making Dilemma</b>	<b>18</b>
Farhad E. Boltchi, DMD, MS	
<b>Computer-Guided Implant Placement; Planning Software, Fixed Intra-oral Reference Points and CAD/CAM Technology</b>	<b>22</b>
Dr. Ali Tahmaseb	
<b>Clinical Review of Minimally Invasive Extraction Techniques</b>	<b>26</b>
Eduardo R. Lorenzana, DDS, MS	
<b>Guided Wound Healing – Trans-mucosal Development in the Esthetic Zone</b>	<b>30</b>
Steven I. Present, DMD	
<b>The Use of Shorter Implants in Clinical Practice</b>	<b>36</b>
Paul A. Fugazzotto, DDS	

## Restorative:

<b>A Simplified Procedure to Ensure Optimal Gingival Contours for the Single Implant-Supported Crown in the Esthetic Zone</b>	<b>44</b>
Richard P. Kinsel, DDS	
<b>Indications, Planning and Restorative Techniques Utilizing the Bone Level Implant – Preliminary Results from a Multi-Center Clinical Trial</b>	<b>48</b>
Will Martin, DMD, MS	
<b>Restoration of Immediately Placed Implants in 3 Appointments From Surgical Placement to Definitive Prosthesis</b>	<b>52</b>
Carlo Ercoli, DDS	
<b>From Casting to CAD/CAM: Technology Affecting Clinicians Today</b>	<b>56</b>
Brody J. Hildebrand, DDS, MS	

## Team Dentistry:

<b>Optimizing SLActive® Surface Technology to Reduce Treatment Time, Maximize Predictability and Increase Patient Satisfaction</b>	<b>62</b>
Robert A. Levine, DDS	
<b>The Interdisciplinary Treatment of Patients with Hypodontia and Oligodontia</b>	<b>68</b>
Nadine Brodala, DDS, MS	
<b>Loading Protocols for Completely and Partially Edentulous Patients</b>	<b>72</b>
Dean Morton, BDS, MS	
<b>Achieving Maximum Esthetic Results through Proper Laboratory Communication</b>	<b>76</b>
Vincent W. Meng, DDS, PC	



**Robert A. Levine, DDS** maintains a full time practice in Northeast Philadelphia focusing on Surgical Implant Placement, Cosmetic Oral Plastic Surgery Procedures, Regenerative Therapy, Adult Orthodontics and Oral Medicine. He is Chairman Emeritus of Periodontics at Albert Einstein Medical Center (1984-2003) and presently is Clinical Associate Professor of Periodontics in the Post-Graduate Department of Periodontics, Periodontal Prosthesis and Implantology at the University of Pennsylvania School of Dental Medicine. Dr. Levine is a Fellow of the International Team for Implantology (ITI) and a Fellow of the College of Physicians in Philadelphia, PA. He is a visiting lecturer at Temple University, New York University, Nova Southeastern University and University of North Carolina Schools of Dentistry. Dr. Levine is a Diplomate of the American Board of Periodontology and serves on the Editorial Boards of five international scientific journals.

## Meet the ITI Fellow: Robert A. Levine, DDS

### Why did you join the ITI?

My history with the ITI goes back to 1990 when Max Listgarten, one of my mentors/professors at the University of Pennsylvania who had spent a year in Switzerland doing research, invited me to hear about a Swiss implant system. I was not familiar with the 2 presenters at the time. However, I was truly impressed with the results they presented.

Danny Buser and HP Weber discussed surgical and restorative perspectives and demonstrated impressive results, with both the mandible and maxillae being nearly equal in success. Since 1986, I was having the experience of Branemark failures in soft bone (Type 4) in the posterior maxilla, as reported by Jaffin and Berman. When Drs. Buser and Weber presented the results of their early studies on the TPS surface and the system's simplicity, I was "converted".

I started placing Straumann implants in early 1991. They have been my implant of choice since then. From a periodontist's standpoint, I was also impressed with Danny's discussion of incision design, the incredible soft tissue healing of tissue level implants and the importance of maintaining keratinized gingiva. Here was an oral surgeon who spoke like a periodontist! While Branemark single tooth studies in the 1990s reported a significant problem with screw-loosening, our experience was quite the contrary.

During my first visit in 1993 to an ITI World Symposium, in Basel, I was introduced to Frank Higginbottom, Tom Wilson and others. As a result of our discussions regarding the Staumann implant, Morse taper and lack of prosthetic problems, along with similar success rates to those of the Swiss, we co-authored a series of retrospective studies on Straumann single tooth implants in posterior applications (JOMI 1997, 1999, 2002, 2007) with other clinicians around the country. This experience got me involved early in my career and has made an impact since then.

### Why do you think Fellowship is important?

For two primary reasons. I am able to raise my level of clinical practice through my interactions with others around the country and world-wide, as we share clinical techniques to improve our patients' outcomes. I strongly believe that the best professional decision I have made was getting involved and staying involved with the ITI. The second reason is the camaraderie. Life-long friendships have developed amongst the Fellows and Members. It continues as we enlarge the US ITI Section. We enjoy seeing each other at each of the Fellows business meeting and US and World Symposiums. The integrity of the Fellows, with a strong desire for seeing "the Evidence," is an important aspect of what we all strive for, unlike most implant companies. The ITI is truly unique in its philosophy and message in dentistry.

### What do you see as the value of the US ITI?

Hands down the quality of the people involved and the educational programs that are part of The US ITI and World Symposiums. The ability to continue to stay ahead of the curve with a strong foundation based upon the literature furthering my personal ambition to be the best I can be for my patients and for myself. The "bar" continues to be raised through what I learn from my colleagues and friends.

### How has the US ITI helped you?

My desire to run clinical in-office studies with fellow clinicians from the mid-1990s, which continues today with ITI Fellows and Members who strive for quality clinical publications, could not have happened without my involvement in the US ITI. In addition, my involvement produced our Philadelphia-based local ITI-funded (from ITI Central: Basel, Switzerland) Study Club, which I co-direct with Joe Fiorellini. In conjunction with the Philadelphia Dental Implant and Perio-Prosthesis Study Club, which I have

directed for over 25 years, the ITI has contributed to my continuing education professionally. Many of the guest speakers are friends from the ITI who I have had professional relationships with for many years, and who deliver similar messages through the sharing of knowledge to with Philadelphia area colleagues. I am proud of the fact that the ITI, a non-profit organization, is on the fore-front of dental implant and regenerative research, with the most funding for this type of research world-wide.

### What has the ITI done well?

Being literature/evidenced-based is my first thought of what the ITI has done well. This goes hand-in-hand with the Consensus Conferences, which have been held world-wide every 5 years since 1993. My involvement in the August 2008 Consensus Conference in Stuttgart, Germany was a personal highlight of my professional career. It was an incredible experience, with representation from close to 30 countries and 99 participants. The state of the art position papers in implant dentistry from this conference will be published in a special issue of IJOMI. This alone separates the ITI from all other players in the field of implant dentistry. In addition, the quality of the programs put on locally, nationally and world-wide is fantastic. Stressing proper education, and not going direct to generalist dentists to teach them surgical placement without proper training, is ethical and important. Too many companies lack integrity, in my opinion, as they "certify" dentists as ready to be implant surgeons after a week-end course. This is not in the best interest of the patient. It is in the best interest of the company's bottom line. Lastly, the quality of the US ITI publication, *Implant Realities*, is something, as an ITI Fellow, I am very proud of.

**What will you like to see the US ITI do?**

I would like to see more web-based education programs, which we on the education committee are starting to develop. Our first program will feature Professor Dean Morton, formerly of University of Florida at Gainesville, and presently at University of Kentucky at Louisville, on prosthetic management of dental implants. In addition, reaching out more to younger clinicians and graduate students to become involved is important, as evidenced-based implant therapy should go hand-in-hand with their educational goals as post-doctoral students. Sponsoring regional meetings will also help to ensure participation of more members and sharing of knowledge.

**What do you see as the greatest challenges facing dentistry?**

I see the greatest challenges, besides the cyclical economy, as the “driving of the market” by companies and corporations without adequate research. Dental implant companies are a prime example. I was shocked recently when I read that there are close to 150 implant companies world-wide. Only a few, with Straumann in the fore-front, are spending profits in developing better products for our patients. Too few companies spend money on research. This will only give implant therapy a bad name, as many patients have already suffered because of this lack of R&D over the years. Many companies come and go. You do not want to be stuck when your company goes bankrupt, and a solution for a surgical or prosthetic problem cannot be found because the company no longer exists. This has to be mind-boggling for recent dental school graduates. Most students are not taught how to look at the literature critically, to establish a literature-based decision. They are too frequently led by the opinions of dental company representatives. My motto is “show me the studies”.

**What do you see as the greatest challenges facing you in dentistry?**

With the explosion in the fields of regeneration (GTR/GBR), esthetics and implant dentistry, my greatest challenge is keeping up. Thus, I continue to attend many CE courses and continue to teach on a post-graduate level at a number of universities. Teaching keeps me current. Being an ITI Fellow/Member helps in this process tremendously, as the ITI is in the lead with what I do on a daily basis in clinical practice.

**Would you like to add anything else?**

I would like to reiterate that getting involved in the US Section of the ITI, if you have not done so, should be on your agenda for 2009-2010. If you have any questions you can contact me at [RLEVINE@PADENTALIMPLANTS.COM](mailto:RLEVINE@PADENTALIMPLANTS.COM). Thank you Paul for allowing me to share my views on the ITI... keep up the great work at *Implant Realities!*



**Harry Randel, DMD** received his DMD from the University of Pennsylvania School of Dental Medicine in 1983, completed a general practice residency at the Veterans Administration Medical Center in 1984, and earned a certificate in Prosthodontics at the Temple University School of Dentistry in 1986. Dr. Randel currently owns a private practice in Blue Bell, Pennsylvania, and has over 25 years of experience as a practicing prosthodontist and advanced restorative dentist. Dr. Randel remains committed to offering his patients the best possible care, and is an active member in many professional organizations, including the American Dental Association (ADA), the Pennsylvania Dental Association, the American College of Prosthodontists, the Northeast Dental Implant Study Club, the Eastern Dental Society, the Academy of Osseointegration, and the International Team for Implantology. Additionally, he has published articles in various peer-reviewed publications, such as "Treatment and Management of Dentoalveolar Abscesses," Liberty Bell Conference March 1984; "Rotary Reduction, Enamel Microabrasion, and Dental Bleaching for Tooth Color Improvement" Compendium of Continuing Education in Dentistry, January 1998; "Solving Cosmetic Dilemmas in the Esthetic Zone" Contemporary Esthetics and Restorative Practice, June 2001.

## Meet the ITI Member: Harry Randel, DMD

### Why did you join the US ITI?

I was introduced to Straumann implants several years ago through my close association with Dr. Robert Levine and the Philadelphia Dental Implant Periodontal-Prosthesis Study Club. There were many informative and excellent lectures presented by the ITI. I saw the value the ITI offered Dr. Levine and his career. I have utilized the Straumann implants since the early 1990's. Having completed courses in many other implant systems, I felt that Straumann implants offered me the ability to be on the cutting edge of implantology. The network of worldwide clinicians and educators could afford me the most up to date research and information, provided in a practical way for the clinician. Their passion for what they do and how strongly they believe in the organization impressed me. I attended several symposia and felt the comradery, so I decided to become a member. I have applied and have been nominated for fellowship. I look forward to that next step in my affiliation.

### Why do you think Membership is important?

Membership in the ITI is important because it supports the organization and the development of new ideas. It is the strength of the network of Members that allows the exchange of ideas and helps make this organization extremely patient oriented, and supportive for the clinician. The Members I have had the opportunity to converse with and learn from have impressed me. I feel that I am always able to find someone who is willing to discuss any questions I have! This is an extremely important and a valuable benefit of membership.

### What do you see as the value of US ITI?

The international constituency is extremely strong. It is important that the United States be represented, so that trends in the United States are recognized and supported by the international umbrella. The US ITI allows me to stay

involved locally with the cutting edge research and education that the ITI offers.

### How has the US ITI helped you?

It has helped me grow as a prosthodontist by providing me with the most up to date research, education and developments in the field of implantology. I work extremely closely with the periodontist and oral surgeon to make sure that the implant/implants placed are ideal for the patient. I integrate all the knowledge I have obtained to provide the patient with the best treatment possible. I feel that the information I have gleaned from the ITI has helped to put me in the forefront of my field through the lectures, research and articles and the interpersonal relationships I have established. The team approach is the way I love to practice dentistry. I believe those who are "Jacks of all trades, are "masters of none." Straumann and the ITI foster the team approach, thereby giving our patients the advantage of the expertise of all of the specialties: periodontics, oral surgery, orthodontics, endodontics and prosthodontics. Additionally, I find that when I attend the meetings the fellow attendees are clinicians and researchers with whom I can discuss my most advanced and challenging cases. These interactions have enhanced my ability to grow as a Prosthodontist and treat my patients with the quality care and attention I value.

### What has ITI done well?

The information, research, education and level of concern and care that the ITI provides for the betterment of the field of implantology is what I value. They provide quality symposia with interesting and informative presentations. The ITI is extremely professional and fosters both wonderful professional relationships and an opportunity for self growth. The ITI helps to raise the level of my own practice. I always look forward to attending the meetings.

### What would you like to see the US ITI do?

I am always on the internet and would like to see some more web based programs and information.

### What do you see as the greatest challenges facing dentistry?

With economic concerns, patients need to understand the value of the advanced dentistry we are able to offer. Getting the word out that implants provide a way to predictably replace teeth is key. Once implants become the standard of care, we can overcome the financial challenges, because patients will understand the value of implantology.

Not only are implants the best way to replace missing teeth, they also are appropriate for teeth with questionable prognoses, including those that require several procedures, such as endodontics, crown lengthening, post core and crown. I hope that we can get the word out that implants are the standard of care, not an upscale alternative.

### What do you see as the greatest challenges facing you in dentistry?

There is so much new information and research every day. I value the attention and up to date treatment that I am able to offer my patients. So, it is important that I am able to learn and implement this information in my daily practice. This is a challenge, with all of my other day-to-day responsibilities. At the same time, it is a priority. Being a part of the ITI, with its publications, symposia, and the Implant Study Club, helps me to meet this challenge.

### Would you like to add anything else?

My association with the ITI is an extremely rewarding association, both personally and professionally. I look forward to my continued involvement.



International Team  
for Implantology

In times of economic uncertainty,  
making wise decisions is key.  
Which is the one event in implant  
dentistry you cannot afford to miss?

ITI  
World  
Symposium  
Geneva, Switzerland  
April 15–17  
2010

30 Years of Leadership and Credibility

- Listen to the views of top experts
- Access a maximum of information
- Find out about approaches you can apply immediately
- Experience the latest in implant dentistry live

Go to [www.iti.org](http://www.iti.org)

The ITI – International Team for Implantology – is an independent academic organization that is dedicated to spreading knowledge and promoting evidence-based methodologies related to implant dentistry.



**John-Michael Stewart, DMD** attended Southern Methodist University where he received a bachelor's degree in Psychology and Biology in 1993. He graduated Magna Cum Laude in 1998 with his dental degree from Boston University School of Dental Medicine and completed specialty training at University of Texas-Southwestern Medical Center and Parkland Memorial Hospital in 2004. During this time, he received a medical degree from UT-Southwestern Medical School in 2002.

## The Role of Oral and Maxillofacial Surgeons in Implant Dentistry

Dental implant therapy has evolved dramatically since its inception. It is now not only driven by stability and function, but also by the natural appearance of the restoration over time. A great smile which is comfortable has become the standard by which implant dentistry is measured by patients and practitioners alike. Treatment philosophies and procedures that were once prominent have been replaced by newer approaches based upon a wealth of information rooted in over a decade of outcome assessments.<sup>1,2</sup> The implant, therefore, must be in a position to accommodate these newer criteria.

Initially, medical surgeons introduced implant therapy into dentistry from orthopaedics. Dental surgeons, were placed into the leadership position of the implant team. However, since implants have become predictable with regard to osseointegration and function, it is more common for current treatment modalities to be driven by the planned restoration(s) and the potential for an esthetic outcome, rather than the available bone for implant placement.

Oral and maxillofacial surgeons and their association have forged ahead to meet this new definition of success. The American Association of Oral and Maxillofacial Surgeons, in the 1990's, was one of the first organizations to host an implant conference promoting the team approach. Leading researchers and clinicians have expanded the indications and predictability of providing an ideal foundation for implants. Drs. Daniel Buser, Robert Marx and Edward Anitua have contributed greatly to the scientific knowledge base related to hard and soft tissue grafting procedures and the role of growth factors and bone morphogens.<sup>3-5</sup> Innovative clinicians, such as Mike Block, Anthony Sclar, Ole Jensen, Michael Pikos, Jim Ruskin and Jay Malmquist have either developed specific hard or soft tissue grafting procedures or fine-tuned existing techniques and, more importantly, shared their innovations with colleagues.<sup>6-9</sup>

These leaders have crossed the line between specialties, thus achieving the best possible results for patients. Along with well-published periodontists, such as Paul Fugazzotto, Dennis Tarnow, Maurice and Henry Salama, etc., they

have helped blur the artificial line between the dental specialties. Dr. Sclar coined the term "Implant Surgeon", in his 2003 textbook. This term described the doctors who have put in "hard time", with years of additional training and continuing education, irrespective of their particular specialty or formal and informal postgraduate work.

It is common knowledge that oral and maxillofacial surgeons are dentists who undergo four to six years of postgraduate residency training. A strong foundation is built in dentoalveolar and maxillofacial reconstruction, providing unique qualifications to handle complex cases such as an atrophic jaw or a large defect resulting from trauma or pathology. Training in orthognathic and facial cosmetic procedures offers skills needed in esthetic implant cases requiring soft and hard tissue reconstruction. A formal anesthesia and medicine background is critical in handling fearful and medically difficult patients. In addition, cases requiring surgical procedures in a hospital setting typically necessitate an oral and maxillofacial surgeon.

Bone and soft tissue grafting are often required to provide an optimal result. Maurice Salama has reminded us: "The tissue is the issue; but the bone sets the tone." Oral and maxillofacial surgery is a specialty built upon the ability to graft bone. Harvesting cortico-cancellous bone autografts is a routine part of our practices. Achieving alveolar width and height with grafts and osteotomies allows implantation outside of the framework of the residual alveolar ridge.

In addition, oral surgeons can make such procedures affordable by performing them in the office with appropriate sedation or general anesthesia. These are wonderful adjuncts for fearful patients. Fear of dental implant surgery is one of the primary reasons people do not proceed with needed therapy.<sup>10,11</sup>

A visit to the oral surgeon may mean the first discussion of implants. Many patients arrive complaining of pain, infection, pathology or trauma. In a majority of cases, these people are then introduced to the possibilities of dental implants. A rapport and trust is established, again demonstrating the oral

and maxillofacial surgeon's key role on the "Implant Team."

While patients seek dental implants, the reality is that they are really asking for teeth. Because of this fact, the restorative dentist has much at stake in the final result and will need the support of a practitioner with the experience and passion to build a firm foundation and a mask of a soft tissue in the "transition zone." Restorative dentists should tap into the highly experienced members of the "Implant Team," the oral surgeons.

### References

1. Belser U, Buser D, Higginbotton F. **Consensus Statements and Recommended Clinical Procedures Regarding Esthetics in Implant Dentistry.** *Int Journal of Oral Maxillofacial Implants* 2004;19 Suppl: 73-4.
2. Buser D, Martin W, Belser U. **Optimizing Esthetics for Implant Restorations in the Anterior Maxilla: Anatomic and Surgical Considerations.** *Int J Oral Maxillofac Implants* 2004;19 Suppl: 43-61.
3. Anitua E. **Fibroblastic Response to Treatment With Different Preparations Rich in Growth Factors.** *Cell Proliferation* 2009;42:162-70.
4. Marx RE. **Bone and Graft Healing.** *Oral and Maxillofacial Surgery Clinics of North America* 2007;19:455-66.
5. Buser D. **Horizontal Ridge Augmentation Using Autogenous Block Grafts and the Guided Bone Regeneration Technique with Collagen Membranes: a Clinical Study with 42 Patients.** *Clin Oral Implants Res* 2006;17:359-66.
6. Sclar AG. **Soft Tissue and Esthetic Considerations in Implant Dentistry.** *Quintessence Publishing*, 2003.
7. Jensen OT, Block M. **Alveolar Modification by Distraction Osteogenesis.** *Atlas of Oral and Maxillofacial Surgery Clinics of North America* 2008;16:185-214.
8. Malmquist JP. **Complications of Hard Tissue Grafting for Implant Placement.** *International Journal of Oral and Maxillofacial Implants* 2003; 18:768-9.
9. Pikos MA. **Atrophic Posterior Maxilla and Mandible: Alveolar Ridge Reconstruction with Mandibular Block Autografts.** *Alpha Omegan* 2005;98:34-45.
10. Walton JN, MacEntee MI. **Choosing or refusing Oral Implants: a Prospective Study of Edentulous Volunteers for a Clinical Trial.** *Int J Prosthodontics* 2005; 18: 483-8.
11. D'Eramo EM, Bontempi WJ, Howard JB. **Anesthesia Morbidity and Mortality Experience Among Massachusetts Oral and Maxillofacial Surgeons.** *Journal of Oral and Maxillofacial Surgery* 2008;66:2421-33.



**Robert C. Vogel, DDS** graduated dental school from Columbia University in New York City before completing a combined residency program at Jackson Memorial Hospital, Mount Sinai Medical Center, and Miami Children's Hospital in Miami, Florida. He maintains a full-time private practice in Palm Beach Gardens, Florida in implant prosthetics and reconstructive dentistry working closely as a team member with several specialists providing implant-based comprehensive treatment as well as conducting clinical trials and providing clinical advise to the dental attachment and implant field. Dr. Vogel has developed and collaborated on the development of several prosthetic components and techniques currently in use in implant dentistry today. He lectures internationally on implant dentistry focusing on simplification, confidence and predictability of implant prosthetics through ideal treatment planning and team interaction. He has published numerous scientific articles on implant dentistry and is a Fellow of the International Team for Implantology.

## The Importance of the Restorative Dentist in Delivering Comprehensive Patient Care

Upon being asked as a Restorative Dentist to submit an editorial to *Implant Realities*, I was forced to rethink why I do what I do, and simply to hide behind the literature or pretty clinical images. Composing an editorial on the importance of the restorative dentist delivering comprehensive care was more difficult than actually delivering comprehensive care. To explain this, I must state that my most predictable, productive, stress free clinical results are only obtained through providing my patients comprehensive care.

First, I would like to explore the role of the restorative dentist not only as one of the members of the treatment team, but more significantly as the conductor in orchestrating and directing care. Finally, I will attempt to identify the risk to our patients, practice and self when falling victim to not providing comprehensive care.

The demands of the restorative dentist today are greater than the conventional "General Dentist" of the past due to the need to be cognizant of the multitude of technologies and techniques available in all specialties. Proper initial evaluation and diagnosis of a patient's status, with an active knowledge of resources available from other specialties, is the first requirement. There is too much to know and be proficient at to be an island onto oneself. The awareness of all treatment modalities, with a proficiency in restorative materials and techniques, leads to roles as: Master Planner, Patient Advocate and Finisher, coordinating all resources. Patients are bombarded by print and electronic advertising, as well as friends' advice. The trusted restorative dentist's role continues as the patient is guided through an appropriate thought process. Recognizing and educating patients in the need for other specialty evaluation or treatment is not to say that the restorative dentist cannot perform procedures himself. However he must obtain the advanced education and invest in technology and staff training necessary to ensure he or she not perform care outside his or her limitations. Even the finest conductor relies on others with commitments to master their instruments, to ultimately make him shine the

brightest. There is a comforting reassurance when working in a team of specialists, where not only is a second opinion built in, there is also reduced and shared potential liability should a complication arise. As a side note, I must recognize the restorative dentists in remote areas where access to treatment is an issue. I've met many such practitioners over the years, and humbly commend those who strive to meet the challenge.

### Summary

Recognition, diagnosis and referral for specific needs is more practical than having a complete knowledge, keen ability and financial investment to provide ideal care. Having an acute awareness of all restorative materials, techniques and necessary equipment is in itself a full time specialty to master in your domain.

Regarding Comprehensive vs. "Patched" Care: I had an epiphany about 4 years into my 23 years of practice. Returning home from a national study club symposium, I realized providing emergency solutions to many patients was keeping me busy, stressed and less than ideally productive. It was an easy trap to fall into: a patient's request to "fix this tooth" and meet their expectations at an immediate and minimal cost, while not addressing the etiology of their emergency. These patients inevitably returned with another emergency to disrupt a potentially productive day. Now they were less happy and expected an immediate fix again. It wasn't until I took a stand with all patients, stating without comprehensive care I would not continue to treat them, that my practice and personal satisfaction took off. Through comprehensive examinations and treatment planning, emergencies were reduced to an occasional loose provisional restoration while patient care, staff satisfaction and practice productivity escalated to new heights. This philosophy caused many patients not to continue treatment in my practice but caused many more to arrive. I'm a strong believer in "like refers like". I had to come to the realization that comprehensive care is first and foremost in the patient's best interest, and then make certain they understood and

accepted this fact to begin treatment. This is not to say that patient financial and personal constraints are ignored; to formulate a unique plan that provides for stability with control of pathology until a final goal can be met is a great aid in such situations.

Presenting comprehensive care provides a clear direction of treatment based on a final result with long-term success. While for some patients this may take longer than others, we are always moving forward. This clear vision provides more precision, productivity and profitability, and is overwhelmingly based solely on Providing Patients Ideal Care.



**Jay R. Beagle, DDS, MSD** is a Periodontist specializing in periodontal plastic and reconstructive surgery and dental implant surgery. He maintains a private practice in Indianapolis, Indiana. Dr. Beagle lectures nationally and internationally, and continues to pioneer, refine, and teach surgical techniques to remain at the forefront of periodontal esthetic and implant dentistry research and development. Dr. Beagle is a Fellow of the International Team for Implantology (ITI), the American Academy of Periodontology, the Academy of Osseointegration, the European Academy of Osseointegration, and the International College of Dentists. Trained at the Indiana University School of Dentistry, Dr. Beagle received his Periodontal Certificate and Masters Degree from the University of Kentucky. Published frequently, Dr. Beagle has authored and co-authored numerous articles in dental literature.

## The Role of the Periodontist in the Field of Dental Implants

I have been asked to write a brief commentary on the importance of the Periodontist in comprehensive patient care. Having completed a residency program in Periodontics 25 years ago, I can personally attest to the paradigm shift evident in this specialty. This paradigm shift is not at the expense of already established periodontal postulates, but rather represents an expansion of Periodontists' understanding of and contribution to comprehensive patient care.

Having been trained in periodontal prosthesis, Periodontists are well versed in the concept of comprehensive care. As introduced by Amsterdam and Cohen many decades ago, periodontal prosthesis provided a system by which to carry out appropriate record taking, comprehensive diagnosis, and detailed multidisciplinary treatment planning, prior to the initiation of active therapy. Application of these principles to implant therapy affords unique and significant advantages. Rather than focusing on "filling the space", Periodontists take into consideration the overall clinical picture, and help develop the most advantageous treatment algorithms for an individual patient in a given situation, in conjunction with the other members of the dental team.

The paradigm shift which has occurred regarding our understanding of periodontal diseases and their relationship to overall patient health further underscores the valuable contributions Periodontists make to comprehensive patient care.

For years, our understanding of the etiology of periodontal disease was focused upon a bacterial infection caused by an accumulation of sub-gingival plaque. This phenomenon, ranging in form from mild gingivitis to severe periodontitis, has been shown to affect three out of four Americans.

However, in recent years oral health, specifically periodontal health, has been definitively linked to the overall health of our patients. Oral health has been associated with cardiovascular disease, diabetes, kidney disease, rheumatoid arthritis, and pre-term births.

Contemporary research has enabled a dynamic understanding of the specific biologic events which connect periodontal disease to the afore-mentioned systemic health problems. Research and the related immunoinflammatory concepts suggest that the loss of bone around teeth in severe periodontal disease is caused by the host's inflammatory response to the bacterial infection, rather than just bacterial plaque, as previously believed.

This new understanding of the inflammatory process, along with the Periodontist's unique expertise in recognizing, diagnosing, and treating inflammation around both teeth and dental implants, has involved the Periodontist even more significantly in comprehensive patient care. As Periodontists immerse themselves in the literature, research, and science, they position themselves as critical participants in overall care. Indeed, the specialist best trained to determine when repair and regeneration is the ideal treatment for retaining teeth for a patient, or when extraction and the placement of dental implants is warranted, is the periodontist.

As dental professionals, our long-term goal has always been optimization of our patients' overall health. As Periodontists continue to research and engage themselves in this ever-evolving understanding of the relationship of periodontal inflammation to systemic health, we must broaden our perspectives to continually undertake a more comprehensive approach, and to collaborate more consistently with patients' physicians. Through this comprehensive and more collaborative approach, and by applying new diagnostic and risk-assessment algorithms and new treatment modalities to patients having severe and demanding dental problems, the Periodontist can more fully realize his/her role in achieving better overall health and comprehensive care for their patients.



**Jeff Singler** began his career as a private technician in 1974 in Dallas, TX. In 1979 he opened his own lab focusing on complex restorative cases and later, implant restorations. He has lectured and consulted on these subjects at meetings around the country and is an individual with the skill and passion to provide the dental restorations that allow his patients to function with trouble-free comfort for years.

## Why A Laboratory Technician is Important in Comprehensive Treatments

As with any endeavour the amount of planning and coordination required to have a successful outcome is relative to the complexity of the task at hand. Obviously the planning needed to install a basketball hoop is much less than that needed to build a three-story office building. So it is with the restoration of teeth or implants. A single tooth can be very simple, predictable and a routine procedure. However, a complex multiple tooth treatment is quite different with a number of specialists contributing to the successful completion of the treatment. It is rarely simple, predictable, or routine. A comprehensive well thought out plan is imperative to assure a positive outcome. This plan must be developed prior to any procedures taking place and should include input from all of the dental team including the laboratory technician.

Development of a precise mock up of the final restoration prior to starting treatment will allow the restorative team to see the critical points of the treatment and take the necessary steps to avoid unexpected mid-treatment complications. This will also allow clinicians to arrive at a reasonable fee for the treatment. A complex implant restorative case is no place for on the fly engineering. Given a set of diagnostic casts, photographs, and appropriate radiographs a preliminary treatment plan can be rendered. With a preliminary idea of the final outcome the dental technician can create a diagnostic workup that replaces teeth as well as hard and soft tissue volumes and restores the dentition to an optimum condition. This can then be the starting point for a meeting of the team to determine if the outcome is realistic and if so what procedures will be required to attain the outcome. Grafting needs as well as periodontal issues will be much clearer than the traditional eyeballing a radiograph method. Concerns of the restorative dentist can be heard as well as technical and materials limitations that the technician anticipates. Upon agreement by the team, the changes to the mock up are executed and the patient is shown what the team feels is a reasonable expectation and at the same time has a very visual tool with which to explain the complexities of the procedures to be performed.

From this point forward this mock-up of the plan is used to keep the case on track and insure continuity in the long treatment process.

From this model we develop several aids that help keep the case true to the treatment plan.

1. Guides for bone grafting
2. Implant surgical guides
3. Stents or copings for provisionalization
4. Laboratory selection of components
5. Information for fabrication of tissue management provisionals
6. Guides for the fabrication of final implant frameworks
7. Guides to assure final ceramic fabrication is within design envelope.

While the investment in a diagnostic mock up is not insignificant, it is relatively inexpensive insurance in the big picture of an expensive treatment plan. The patient deserves the very best chance of a good outcome and a preliminary workup is a simple and predictable way to help assure a successful treatment.



**Frank Celenza, DDS** is certified in both Orthodontics and Periodontics. He received his Periodontal certificate from University of Pennsylvania in 1986 and his Orthodontic certificate from New York University in 1988. He has authored numerous publications in dental literature, has been involved in Post-Graduate teaching for over 15 years, and maintains a private practice in Manhattan. Dr. Celenza comes from a long line of dentists; both his father and brother are prosthodontists.

## The Importance of the Orthodontist in Delivering Comprehensive Care

The practice of dentistry has experienced significant changes and advancements over the years. While new treatment modalities always have an effect throughout dentistry, not all of the specialties are equally impacted. The advent of implant dentistry has caused profound changes in the surgical specialties, and has similarly affected the restorative fields. However, orthodontists, although aware of new treatment options, did not necessarily have to reconsider all aspects of their care, as did the aforementioned clinicians. Nevertheless, the trickle down effect has resulted in the increased importance of precise tooth position, about which the orthodontist must now be cognizant.

For example, the congenitally missing maxillary lateral incisor is a relatively frequent case type confronting orthodontists, surgeons and restorative dentists. While this case type is usually bilateral, unilateral situations are also common. The unilateral congenitally missing lateral incisor is commonly associated with a contra lateral peg incisor. Historically, these cases were restored with fixed bridgework of a variety of designs, ranging from bonded Maryland bridges to full coverage fixed partial dentures. The orthodontic preparation necessary for these restorations centered around space management at the level of the clinical crown. Exact parallelism of the roots was often times overlooked and perhaps not that critical, as the restoration would have certain corrective aspects to it, particularly in the instance of full coverage.

However, with the widespread success of implants as a source of tooth replacement, the need for spatial management now extends the entire length of the root for many reasons. Surgical placement of the implant stipulates that roots be paralleled so that they do not encroach upon the implant site, helping to minimize the risk of injury to the neighboring teeth during implantation. Second, as the teeth

on either side of the implant site will no longer be prepared and restored, the natural clinical crown is preserved with its inherent contours, and so must be accurately positioned to harmonize with the rest of the dentition. Consequently, pre-restorative, and even pre-surgical orthodontic intervention, is often essential in these cases.

Other examples of the need for orthodontic intervention in comprehensive care abound. Restorative dentistry has arguably become more conservative over the last few decades. Full coverage restorations are not as commonly planned as in the past. Tooth preservation as a trend is further enhanced by the dramatic drop in the incidence of caries we have all observed. As a result, the increased demand by the public for improved cosmetics is now more frequently satisfied by orthodontic intervention. Teeth that may be malpositioned and were previously treated by restoration are now orthodontically repositioned with great efficiency, preserving their natural beauty, health, and structural integrity.

The rise in adult orthodontics that most orthodontic practices reports substantiates these assertions, as does the development of cosmetic appliances such as clear brackets, lingual braces and the explosive growth of systems such as Invisalign. Patients are beginning to appreciate less invasive orthodontic alternatives to irreversible restorative options. Similarly, dental practitioners should be considering how orthodontic intervention pre-restoratively will often result in less tooth preparation and more conservative restorative intervention when properly sequenced, executed and coordinated.

An orthodontists' intervention in comprehensive care should not be confined to pre-restorative or pre-surgical preparation of a case. The orthodontist must be viewed as an integral part of

an implant team. The facilitation of orthodontic therapy when implants are planned, placed and then harnessed as part of an orthodontic appliance is dramatic. However, this treatment modality does require a shift in thinking, and a change in treatment sequencing, to be fully realized.

The ability to provide new treatment options to patients when implants are placed and used for orthodontic advantage as part of appliance mechanotherapy is profound. Advantages include the transformation of extraction cases into non-extraction cases, or the possibility that patients not considered candidates for conventional orthodontics can now be treated. Treatment plans must be sequenced differently, so that implants are placed preparatory to orthodontic care. This represents a reversal of conventional timing.

The rise in popularity of implants has finally begun to effect the specialty of orthodontics, and the aforementioned pre-orthodontic implant falls into one of two categories: permanent or temporary.

Permanent implants are destined to function as dental restorations, and exist in dentate locations. When such a dental implant will be utilized orthodontically, it is frequently provisionalized and then harnessed as a conventional tooth would be for inclusion in the orthodontic appliance. The difference is that an osseointegrated implant will function as an absolute source of anchorage. It can be loaded in such a way as to permit dramatic and expedient movements.

Temporary implants may be utilized, and are often located outside of the dental arch (ie: buccal cortex, retromolar and mid palatal). Implants which are destined for explantation post-orthodontics have been termed temporary anchorage devices (TAD). These devices also offer great efficiency and expediency, but must be properly planned and sequenced to fully

exploit their advantages.

Consequently, it is no longer acceptable for the orthodontist to single handedly treatment plan interdisciplinary cases, waiting for the orthodontic aspect of therapy to be completed before referring the patient to the appropriate surgeon or restorative dentist for continuing care. All treating clinicians need to be part of the treatment planning team from the outset, as factors that affect their aspects of therapy must be considered before arriving at and initiating a treatment plan. For the orthodontist to take full advantage of available supportive modalities, he or she must become an intrinsic part of the treatment planning team, and function as a conversant and accessible member.



**David L. Cochran, DDS, PhD** is a graduate of the University of Virginia and received his D.D.S., and Ph.D., in Biochemistry from the Medical College of Virginia (MCV). He also was trained in Periodontology from the Harvard School of Dental Medicine. Dr. Cochran is Professor and Chairman of the Department of Periodontics at The University of Texas Health Science Center at San Antonio, Dental School. Prior to his appointment at San Antonio, Dr. Cochran was Director of Postgraduate Periodontics at MCV. Dr. Cochran is a member of many professional dental organizations and is a Diplomate of the American Board of Periodontology. He is a fellow of the American College of Dentistry and the International College of Dentistry. Dr. Cochran has published numerous scientific articles and abstracts on various periodontal biochemistry and implant topics. He has received awards for his research work at both the national and international levels. Dr. Cochran is an active basic science and clinical researcher who has received funding from both the NIH-NIDR and private industry.

## Beyond Titanium; Where No Implant Has Gone Before!

The basis for reliable tooth replacement with endosseous dental implants in patients is the integration of the implant into the patient's alveolar bone. During this process a relatively large core of bone is removed from the patient, resulting not only in injury but also compromised integrity of the bony and vascular architecture. A potential advancement in the replacement of teeth with dental implants would be a procedure that reduces both the amount of injury to the bone and the amount of vascular and bone tissue removed in the core. Both these goals could be achieved by the use of a smaller diameter endosseous dental implant.

Of additional importance for reliable tooth replacement with endosseous dental implants is the use of an implant that has: (1) biocompatibility; (2) sufficient strength not to break or fracture under occlusal load; and (3) physical and chemical surface characteristics that are osteopromotive. Historically, Institut Straumann AG has been a proven pioneer and leader in this area while other companies have struggled, tried to mimic, or made alternatives that have been less reliable. For example, Institut Straumann, with its long history of expertise in materials science, understood that titanium metal was available in four grades and the strength of the metal could be improved by cold working the highest grade titanium (grade IV). This added strength is particularly helpful in the posterior aspects of the jaws where the occlusal forces are greatest. The decision by Institut Straumann to use cold worked grade IV titanium for its implants was a wise one as few fractures of its standard diameter (4.1 mm) solid screw have ever been reported. In contrast, the use of the lowest grade titanium (grade I) by some companies resulted in many fractures of standard implants when used for single tooth replacement in the posterior aspect of the jaws. To try to compensate for using an implant that was inadequate in strength, the manufacturer recommended that the clinician either use multiple implants to replace larger molar teeth, and/or to place implants in a non-linear arrangement. This is one example of how Institut Straumann and the International Team for Implantology (ITI) have used science

and investigation to produce reliable high quality products for tooth replacement in patients.

The ITI and the Institut Straumann have continued to use science and investigation to pioneer other innovations for endosseous dental implants. Another example of such leadership in the field is in the area of surface characteristics. With its long history in metal materials science, Institut Straumann realized the importance of a roughened surface for bone apposition, leading to the use of a titanium plasma-sprayed surface for its endosseous dental implants rather than a machined (turned) surface. Since then, extensive scientific investigations by the ITI and the Institut Straumann involving *in vitro* animal and *in vivo* testing produced significant improvements of the osteopromotive surface, resulting in the patented sandblasted, large-grit, acid-etched (SLA<sup>®</sup>) surface, and more recently, the chemically modified SLActive<sup>®</sup> surface configuration. These innovations have led to osteoconductive subtractive titanium surfaces without porosity that result in osseointegration with larger bone-to-implant contact areas and high removal torque values at early healing times. These characteristics allow earlier loading of the implants by cutting the traditional healing times in half, or better, without compromising reliability or success in patients.

The ITI and the Institut Straumann have since continued to be pioneers and innovators in implant dentistry and this article (and presentation at the annual U.S. ITI Congress in Scottsdale, AZ, USA on April 25th, 2009) will describe some experimental work on a new dental implant with a novel material composition based on the well known metal titanium. The chemical element zirconium can be found in ceramics in dentistry, but also exists as a metal. Institut Straumann has been working on the development of a composite metal implant made up of both titanium and zirconium. This combination can dramatically increase the strength of pure titanium, but a more difficult question was whether the SLActive surface could be

created on the metal composite in order to retain the enhanced osseointegration behavior of the pure titanium SLActive surface. Other companies neglected this important question and tried to increase the strength of their implants by using a Titanium Vanadium Aluminum alloy (TAV). Besides the disadvantage of not having SLA or SLActive like surfaces on the TAV material, it also contains Vanadium and Aluminium, two elements inhibiting osteoblast growth.<sup>1</sup>

The SLActive surface is based on the SLA surface, created by sandblasting and acid etching. Because two different materials are used in the new implants, the amounts have to be carefully controlled in order to create a surface with the same characteristics as SLActive after both sandblasting and acid etching. After several years of intensive investigation at Institut Straumann, an SLActive surface was produced on the composite titanium-zirconium metal implant. This implant is being manufactured under the name Roxolid<sup>™</sup> and has the advantage of superior strength over existing pure titanium implants. An additional obvious advantage of such a product may be the provision of a narrower implant with the strength of the current standard implant. The second result would be that more narrow ridges could be treated without bone augmentation, thereby increasing indications and further enhancing implant care for our patients.

Essential to new product development is preclinical and clinical testing in animals and humans. The ITI and the Institut Straumann have stood by such a process for many years, and the development of Roxolid<sup>™</sup> is no exception. *In vitro* experiments and materials testing have been performed on Roxolid<sup>™</sup> with encouraging results on the strength of the material and favorable interactions with bone cells. Furthermore, Dr. Jan Gottlow has compared Roxolid<sup>™</sup> implants to pure titanium SLActive implants in the mini-pig maxilla model. These experiments show excellent osseointegration using descriptive histology and functional removal torque testing.<sup>2</sup>

Because of the variability in animal model

testing, the Institut Straumann, continued with thorough investigation by commissioning another animal study to further evaluate osseointegration of the Roxolid™ implant.

This second animal study was performed in the mandibles of nine fox hounds at the University of Texas Health Science Center at San Antonio under the direction of Dr. David Cochran. In this model, mandibular premolars and first molars were removed and the alveolar bone allowed to heal for 4 months. Implants were then placed and healing evaluated both radiographically and histologically. In this particular study, a total of twelve implants were placed in each animal. The pure titanium SLActive implant was alternated with the titanium-zirconium (Roxolid™) SLActive implant, and healing was evaluated after 2, 4 and 8 weeks. Preliminary radiographic findings indicate that, after an initial period of bone remodeling, bone resorption and bone formation became coupled resulting in a stable marginal bone level.<sup>3</sup> Furthermore, the osseous reaction appears similar between both implant types.

The initial conclusions from these experimental studies suggest that the new Roxolid™ SLActive implant is a significantly stronger dental implant with the same chemically active osteopromotive surface as the currently utilized pure titanium SLActive implant. Multiple human clinical trials are ongoing, and results to date suggest successful Roxolid™ outcomes similar to the current titanium SLActive implant. The data therefore demonstrate that the Roxolid™ implant represents another significant innovation in implant dentistry.

## References

1. Steinemann S. **Titanium – the material of choice?** *Periodontology 2000*;Vol. 17, 1998: 7-21.
2. Gottlow J et al. **Preclinical data presented at the 23rd Annual meeting of the Academy of Osseointegration (AO), Boston, and at the 17th Annual Scientific Meeting of the European Association for Osseointegration (EAO), Warsaw.**
3. Thoma D et al. **Evaluation of a new titanium-zirconium dental implant. A comparative radiographic study in the canine mandible. Oral presentation at the 24th Annual meeting of the Academy of Osseointegration (AO), San Diego.**



**Jay R. Beagle, DDS, MSD** is a Periodontist specializing in periodontal plastic and reconstructive surgery and dental implant surgery. He maintains a private practice in Indianapolis, Indiana. Dr. Beagle lectures nationally and internationally, and continues to pioneer, refine, and teach surgical techniques to remain at the forefront of periodontal esthetic and implant dentistry research and development. Dr. Beagle is a Fellow of the International Team for Implantology (ITI), the American Academy of Periodontology, the Academy of Osseointegration, the European Academy of Osseointegration, and the International College of Dentists. Trained at the Indiana University School of Dentistry, Dr. Beagle received his Periodontal Certificate and Masters Degree from the University of Kentucky. Published frequently, Dr. Beagle has authored and co-authored numerous articles in dental literature.

## Tissue Level Versus Bone Level; Is There a Difference?

The use of endosseous dental implants to rehabilitate partially or fully edentulous patients has been well-documented in the literature for over 20 years.<sup>1</sup> The original concept employed the use of a submerged technique, with implants restored using abutments of matching diameters. It was typically advocated that the implant-abutment interface be located at or 1mm apical to the crestal height of bone. Using this protocol, data 1 year following restoration demonstrated crestal bone levels that were typically 1.5-2mm apical to the implant-abutment interface.<sup>2,3</sup> Although not negatively influencing the functional result, this crestal bone remodeling could influence the position of the peri-implant soft tissue height.

A change in implant design and technique (non-submerged) occurred in the early 1980's. Numerous articles reported upon the long term stability and survival of implants using this approach which utilized a roughened titanium surface and a polished transmucosal collar.<sup>4</sup> This transmucosal collar permitted vertical displacement of the implant-abutment interface. Studies have shown that when an implant with a roughened surface is utilized in conjunction with a vertical platform shift, minimal changes in the crestal bone level and the marginal soft tissue level will occur following restoration.<sup>5,6</sup> The location of the implant-abutment microgap appears to be of greater importance than the physical size of the microgap.<sup>7,8</sup>

Recently, clinical studies began exploring the effects of non-matching diameter implant-abutment interfaces, referred to as a horizontal platform switch.<sup>9</sup> Assessing clinical results via radiographs over a 13 year observation period, Lazarra reported significantly less crestal bone remodeling when implants of 5 and 6mm diameters were restored using abutments designed for 4mm diameter implants, even though the microgap occurred at the crestal bone level.<sup>10</sup> Based on a report by Brogginini et al, it is known that when a microgap is placed at or 1mm below the crest of bone, a significant neutrophil infiltrate occurs.<sup>11</sup>

It is theorized that by locating the microgap inward via platform shifting, the inflammatory cell infiltrate is positioned further away from the crestal bone and reduces the inflammatory effect within the surrounding soft tissue and bone.

Zipprich<sup>12</sup> has shown, with in vitro experiments, that abutment movement can occur when a restored implant is loaded.<sup>12</sup> Using hi speed videoradiography, implant-abutment interfaces with flat-to-flat contact have been shown to illustrate significant mobility compared to implant-abutment interfaces with a conical connection. It is theorized that the mobility of the interface (microgap) creates a "micropump", forcing the inflammatory cell infiltrate into the surrounding soft tissues, resulting in crestal bone loss.

Jung et al<sup>9</sup> published an annual study in which implants having a roughened titanium surface and a horizontal platform switch were observed radiographically after 6 months of loading. Minimal crestal bone remodeling was detected, regardless of the location of the microgap relative to the pre-operative crestal bone levels.

When comparing studies which assess crestal bone changes of a vertical platform switch to those of a horizontal platform switch, the data appears to indicate both are superior to a matching diameter implant-abutment connection relative to crestal bone loss. However, a vertically displaced microgap is more favorable than a horizontally displaced microgap. Despite this finding, implant systems with a horizontal platform shift may offer greater simplicity to the less-experienced surgeon and/or restorative dentist than a tissue level implant, when the replacement of a single tooth or contiguous teeth in the esthetic zone is contemplated.

### References

1. Albrektsson T et al. **The long-term efficacy of currently used dental implants: a review and proposed criteria of success.** *Int J Oral Maxillofac Implants* 1986;1(1):11-25.
2. Hermann, JS et al. **Crestal bone changes around titanium implants. A radiographic evaluation of unloaded nonsubmerged and submerged implants in the canine mandible.** *J Periodontol* 1997;68(11):1117-30.
3. Cardaropoli, G, U Lekholm, and JL Wennstrom, **Tissue alterations at implant-supported single-tooth replacements: a 1-year prospective clinical study.** *Clin Oral Implants Res* 2006;17(2):165-71.
4. Buser D et al. **Long-term evaluation of non-submerged ITI implants. Part 1: 8-year life table analysis of a prospective multi-center study with 2359 implants.** *Clin Oral Implants Res* 1997;8(3):161-72.
5. Buser D et al. **Clinical experience with one-stage, non-submerged dental implants.** *Adv Dent Res* 1999;13:153-61.
6. Hartman GA and DL Cochran, **Initial implant position determines the magnitude of crestal bone remodeling.** *J Periodontol* 2004; 75(4):572-7.
7. Hermann JS et al. **Influence of the size of the microgap on crestal bone changes around titanium implants. A histometric evaluation of unloaded non-submerged implants in the canine mandible.** *J Periodontol* 2001;72(10):1372-83.
8. King GN et al. **Influence of the size of the microgap on crestal bone levels in non-submerged dental implants: a radiographic study in the canine mandible.** *J Periodontol* 2002;73(10):1111-7.
9. Jung RE et al. **A systematic review of the 5-year survival and complication rates of implant-supported single crowns.** *Clin Oral Implants Res* 2008;19(2):119-30.
10. Lazarra RJ and SS Porter, **Platform switching: a new concept in implant dentistry for controlling postrestorative crestal bone levels.** *Int J Periodontics Restorative Dent* 2006; 26(1):9-17.
11. Brogginini N et al. **Peri-implant inflammation defined by the implant-abutment interface.** *J Dent Res* 2006;85(5):473-8.
12. Zipprich H, WP Lauer H-C, Lange B, **Micro-movements at the implant-abutment interface: measurements, causes and consequences.** *Implantologie* 2007;15:31-45.





**Farhad E. Boltchi, DMD, MS** received his dental degree from the Medical University of Hannover in Germany and a Certificate in Periodontics associated with a Master of Science degree in Oral Biology from Baylor College of Dentistry in Dallas, Texas. Dr. Boltchi is a Clinical Assistant Professor in the Graduate Periodontics Program at Baylor College of Dentistry in Dallas, Texas and maintains a full-time private practice in Periodontics and Dental implants in Arlington, Texas. Dr. Boltchi has achieved Board Certification status with the American Board of Periodontology and is a fellow of the International Team for Implantology (ITI).

## The Replacement of Hopeless Teeth in the Esthetic Zone with Dental Implants – A Decision-Making Dilemma

### Introduction

The ultimate success of implant therapy in the esthetic zone is directly related to treatment planning and accurate restorative and surgical assessment of the prospective site. Recent advances in our understanding of the biological principles governing the esthetic appearance of the soft tissue frame surrounding natural teeth and dental implants and their incorporation into a comprehensive treatment plan with the careful coordination of the various surgical and restorative techniques has significantly enhanced the predictability of an esthetic outcome of implant therapy in the esthetic zone. Nevertheless, esthetic implant therapy remains very challenging. This is largely due to anatomic limitations and the significant potential for soft tissue complications, especially in conjunction with higher risk procedures such as immediate implant placement and immediate loading protocols. Patients presenting with hopeless teeth in the esthetic zone present a unique challenge to the clinician. This challenge is related to the well documented and inevitable resorptive process that follows the extraction of these teeth. The clinical decision-making dilemma and controversy relates to the choice of which treatment option is best suited to counteract this resorptive process and thereby achieve the most predictable and long-term stable esthetic result.

### Treatment Options

The available treatment options include immediate implant placement, immediate or delayed implant placement after orthodontic extrusion, delayed implant placement with a simultaneous ridge augmentation procedure, delayed implant placement with ridge preservation procedure performed at the time of extraction, and delayed implant placement after a staged ridge augmentation procedure.<sup>1</sup> Each of these treatment approaches is associated with various advantages, disadvantages, and risks for soft tissue complications. In clinical practice, the chosen treatment approach must not only provide a long-term functional result, but must also lead to a long-term stable esthetic result which satisfies the needs and desires of the patient.

### Pre-operative Evaluation

The clinician makes all treatment decisions based upon the pre-operative assessment of the clinical situation in a given patient, in order to choose the most appropriate treatment approach to achieve a successful treatment outcome with a high degree of predictability and a low risk of complications. The pre-operative esthetic risk assessment as proposed by Martin et al.<sup>2</sup> in the ITI Treatment Guide, Vol. 1 outlines 12 risk factors which can be utilized in daily practice to evaluate patients. These factors, encompassing both systemic and local factors, are the medical status of the patient, patient's smoking habit, patient's esthetic expectations, lip line, tissue biotype, shape of adjacent tooth crowns, presence of local infection at implant site, bone level at adjacent teeth, restorative status of neighboring teeth, width of edentulous space, soft tissue anatomy, and the bone defect at the implant site.

### Extraction Technique

Irrespective of the treatment approach chosen to replace hopeless teeth in the esthetic zone, extraction techniques that result in minimal trauma to the hard and soft tissues should be utilized. Even small periostomes, which are designed to be inserted between the alveolar bone and the root of the tooth, may damage vital structures and therefore compromise healing. In order to avoid these complications and to simplify the preservation of the hard and soft tissue anatomy following dental extraction procedures in the esthetic zone, the use of an innovative torque-driven extraction technique (Easy X-Trac System - ATitan Instruments; Hamburg, NY) is recommended.

### Immediate vs. Delayed Implant Placement

The chief clinical decision-making dilemma and controversy is related to the timing of implant placement after the extraction of teeth in the esthetic zone (i.e. whether implants should be placed immediately after tooth extraction into fresh extraction sockets or after varying healing times to allow for soft tissue and hard tissue maturation). A review of the literature clearly demonstrates that both

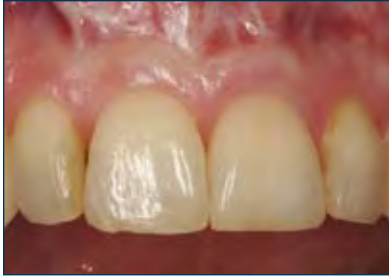approaches result in similar high long-term implant survival rates. However, few studies report on the esthetic outcome for both approaches, especially with regards to long-term stability of the esthetic result.<sup>3</sup> Although there are several advantages associated with immediate implant placement, including a reduced number of surgical procedures, reduced overall treatment time, and optimal availability of existing bone, recent studies report a higher incidence of facial marginal tissue recession using this surgical approach. In order to compensate for the horizontal and vertical resorption of the alveolar ridge following tooth extraction, and thereby minimize facial mucosal recession, several adjunctive surgical and restorative techniques can be utilized such as concomitant hard and soft tissue grating, immediate implant placement without flap elevation, positioning the implant more palatally within the socket to ensure a horizontal buccal peri-implant defect dimension of 2-3mm, and restorative platform switching techniques designed to minimize bone loss at the alveolar crest following restoration.<sup>4,5</sup>

The main advantage of the delayed implant placement treatment approach as evidenced by recent studies is a more predictable and stable esthetic outcome, especially with regards to the occurrence of facial marginal tissue recession. This is largely due to a more controlled surgical technique allowing for a more accurate positioning of the implant and a more predictable contour augmentation via hard and soft tissue grafting.


### Flap Evaluation vs. Flapless Surgery

The major philosophical difference between implant placement with flap elevation and a flapless implant placement approach is the importance of preservation versus the importance of reconstruction. Flap elevation affords the ability to augment and reconstruct the surgical site more predictably, and thereby reduces the risk of complications. Minimally invasive flapless surgical techniques lead to preservation of existing anatomy and thereby can result in superior esthetic outcomes, especially in cases with restorations on

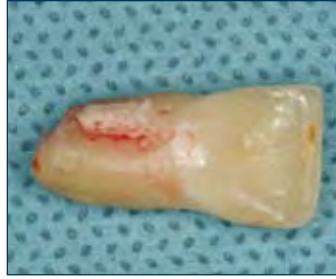**Case 1**



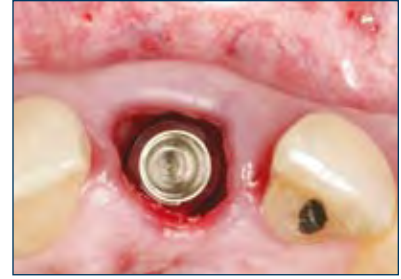**Figure 1** A pre-operative retracted view of a 37-year old female patient's maxillary anterior dentition, with intact gingival architecture.



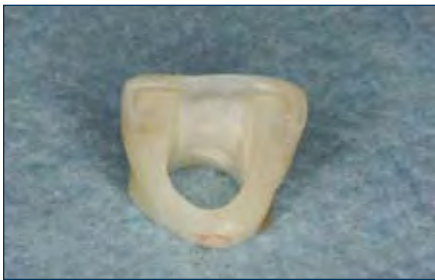**Figure 2** A pre-operative radiograph reveals severe external resorption of tooth #9, rendering this tooth hopeless.



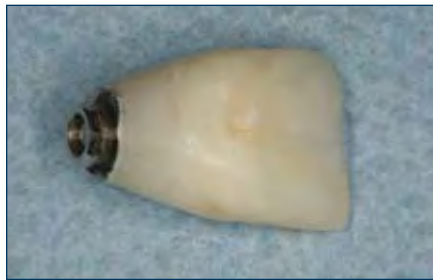**Figure 3** Extracted tooth #9 demonstrates external replacement resorption.



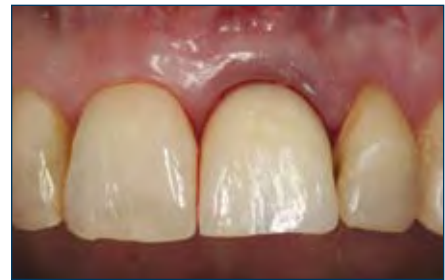**Figure 4** Immediate flapless implant placement has been carried out, without impingement upon the facial osseous plate.



**Figure 5** The sectioned crown of the extracted tooth is modified and acid etched to be used for fabrication of a screw-retained provisional restoration.

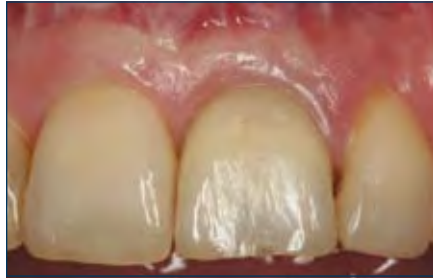

**Figure 6** The modified extracted tooth is converted to an emergence profile screw-retained provisional restoration.

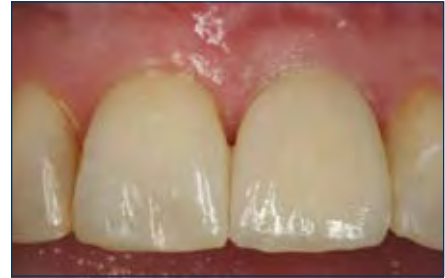

**Figure 7** A view of an immediate implant restoration after insertion of a non-functional provisional restoration.

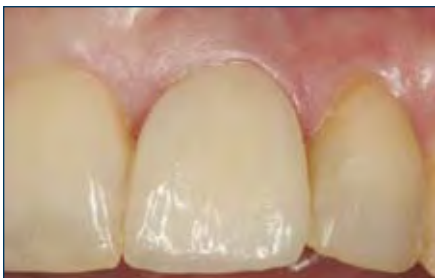**Figure 8**  
A view of an immediate post-operative radiograph after insertion of the immediate provisional restoration.



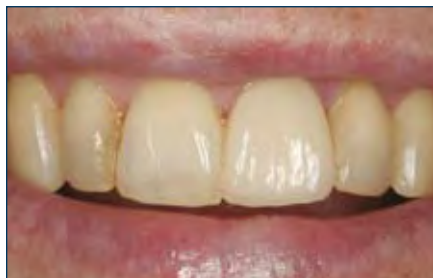**Figure 9** A 2 week post-operative view demonstrates maintenance of the gingival architecture.



**Figure 10** A 3 year post-operative view demonstrates long-term maintenance of a harmonious gingival architecture.



**Figure 11** A 3 year view of the implant restoration #9.



**Figure 12** A 3 year smile view.



**Figure 13**  
A 3 year post-operative radiograph demonstrates physiologic osseous remodeling and excellent maintenance of crestal bone levels.

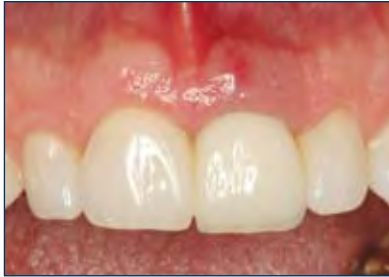adjacent teeth, where flap elevation may result in recession and exposure of the adjacent restorative margins. However, flapless surgery is a blind technique, with a significantly higher risk of complications. These complications may be reduced with the utilization of computer guided or navigational surgical techniques.<sup>6,7</sup>

## Conclusions

When a hopeless tooth in the esthetic zone needs to be replaced with an implant-supported restoration, the clinician must determine which treatment approach will result in the most predictable and long-term stable functional and esthetic outcome. Certain clinical scenarios will benefit from the utilization of minimally invasive surgical

approaches to achieve the most superior esthetic outcome (Case 1, Figures 1-13 and Case 2, Figures 14-27) while other clinical scenarios will benefit from a more traditional multi-step surgical approach to minimize the risk of complications.

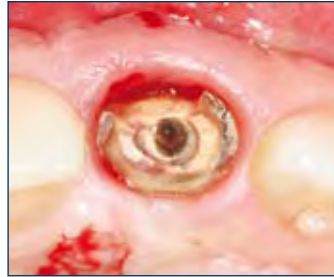## Case 2



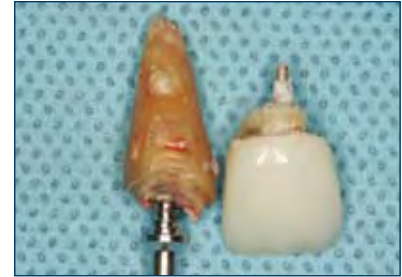**Figure 14** A pre-operative retracted view of a 45-year old male patient's maxillary anterior dentition; tooth #9 exhibits a facial sinus tract due to a deep facial subgingival fracture.



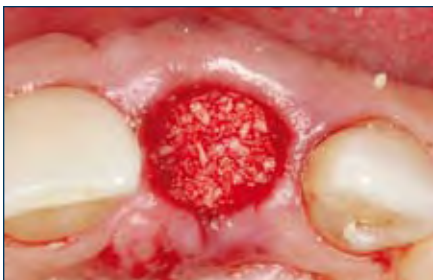**Figure 15** A pre-operative radiograph of tooth #9, with previous endodontic therapy and a post and core crown restoration.



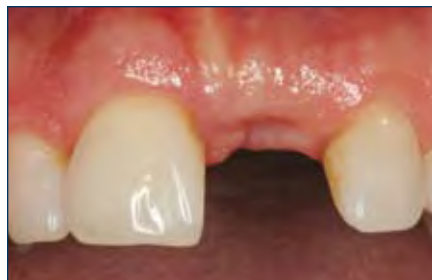**Figure 16** An occlusal view of tooth #9 reveals a deep subgingival fracture, rendering this tooth hopeless.



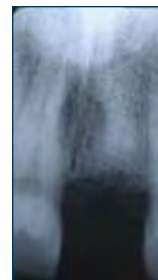
**Figure 17** The tooth #9 is extracted with the Easy X-Trac System®. The deep subgingival fracture is clearly evident.



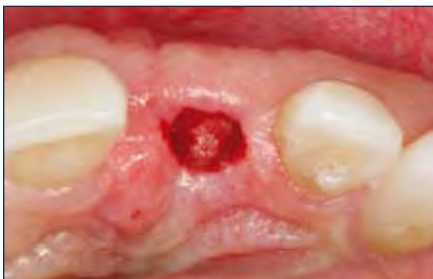**Figure 18** A ridge preservation procedure is performed using a combination of an allograft (Puros Cancellous®) and xenograft (Bio-Oss®) bone graft material, combined with a bovine collagen barrier (BioMend Extend®).



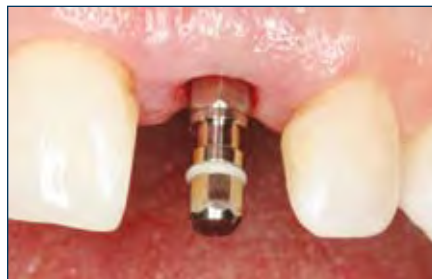**Figure 19** A clinical view after 5 months of healing.



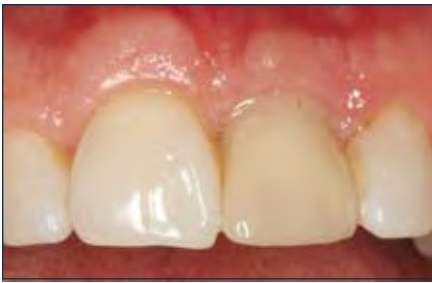**Figure 20** A 5 months post-operative radiograph demonstrates the well integrated bone graft material.



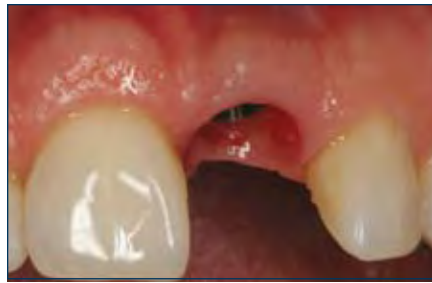**Figure 21** An occlusal view of the punch-type incision performed to access the edentulous ridge at site #9.



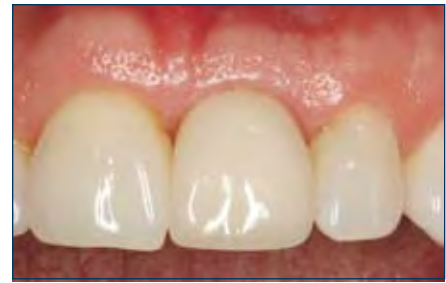**Figure 22** Implant placement site at #9 using a flapless approach is accomplished.



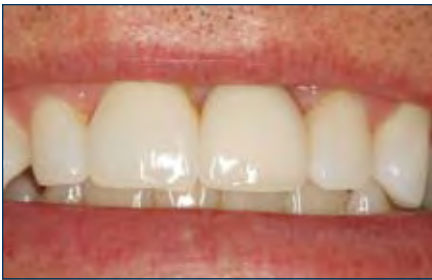**Figure 23** Insertion of a screw-retained provisional restoration is carried out 6 weeks after implant placement.



**Figure 24** A view of the properly conditioned peri-implant soft tissue architecture prior to final impression.



**Figure 25** A 4 year post-operative view demonstrates long-term maintenance of an esthetically pleasing treatment outcome.



**Figure 26** A 4 year smile view.



**Figure 27** A 4 year post-operative radiograph demonstrates excellent maintenance of crestal bone levels.

## References

1. Hämmerle CH, Chen ST, Wilson TG Jr. **Consensus statements and recommended clinical procedures regarding the placement of implants in extraction sockets.** *Int J Oral Maxillofac Implants* 2004;19 Suppl:26-28.
2. Martin WC, Morton D, Buser D. **Diagnostic factors for esthetic risk assessment.** In: Buser D, Belser U, Wismeijer D, editors. *ITI Treatment Guide, Vol. 1: Implant therapy in the esthetic zone: single-tooth replacements.* Berlin: Quintessence 2007. p. 11-20
3. Chen S, Buser D. In: Buser D, Wismeijer D, Belser U, editors. *ITI Treatment Guide, Vol. 3: Implant placement in post-extraction sites treatment options.* Berlin: Quintessence 2008.
4. Belser UC, Grütter L, Vailati F, Bornstein MM, Weber HP, Buser D. **Outcome evaluation of early placed maxillary anterior single-tooth implants using objective esthetic criteria: A cross-sectional, retrospective study in 45 patients with a 2- to 4-year follow-up using pink and white esthetic scores.** *J Periodontol* 2009; 80:140-151.
5. Buser D, Halbritter S, Hart C, Bornstein MM, Grütter L, Chappuis V, Belser UC. **Early implant placement with simultaneous guided bone regeneration following single-tooth extraction in the esthetic zone: 12-Month results of a prospective study with 20 consecutive patients.** *J Periodontol* 2009; 80:152-162.
6. Van de Velde T, Glor F, De Bruyn H. **A model study on flapless implant placement by clinicians with a different experience level in implant surgery.** *Clin Oral Implants Res.* 2008; 19(1):66-72.
7. Chen ST, Darby IB, Reynolds EC, Clement JG. **Immediate implant placement postextraction without flap elevation.** *J Periodontol* 2009; 80:163-172.



**Dr. Ali Tahmaseb** graduated in 1993 from the dental school of Ghent, Belgium. He studied orthodontics and implant dentistry in different academic centers. Dr. Tahmaseb is an ITI-fellow and investigator at the University of Amsterdam, ACTA. He also teaches in the same university in the field of implant dentistry and lectures nationally and internationally on implant dentistry and more specifically in guided surgery and sinus grafts.

## Computer-Guided Implant Placement; 3-D-Planning Software, Fixed Intra-oral Reference Points and CAD/CAM Technology

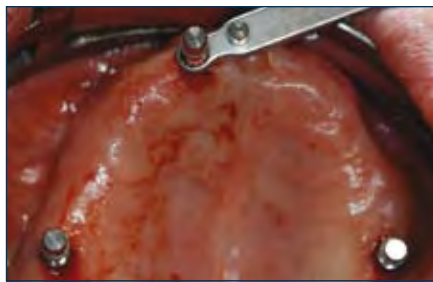### Abstract

The aim of this article is to explain the use of a computer-aided 3D-planning protocol in combination with preinstalled mini-implants and CAD/CAM technology to restore a fully edentulous patient. Mini-implants are used to fix the CT-setup during the CT-imaging and the surgical template during the surgery. The software and 3D realization allow us to plan the ideal implant placement digitally integrating both the future prosthetic and anatomic situations to design the final superstructure. The CAD-designed and CAM-manufactured superstructure is produced digitally with a precise fit, occlusion and aesthetics and is installed directly after the surgery.

### Treatment Protocol

35 patients were included of which 30 patients (16 males; 14 females) with 33 edentulous jaws, have been already treated. The mean age of the treated patients was 62.26 years (range 40-80 year). In general, the patients were in good medical health. All patients were at least edentulous in one jaw for more than 1 year and one patient had already received treatment with dental implants in opposite jaw.

All patients were provided with the reference mini-implants, 3mm in diameter and 4-6mm in length three in each jaw according to a flapless procedure, three weeks prior to treatment surgery. They were distributed triangularly so as they ensure the stability of the future surgical template and in such a manner as not to interfere

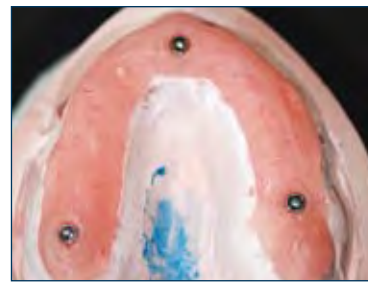

**Figure 1** Three reference mini-implants have been placed in a triangular manner, in positions which will not interfere with final implant locations.

with locations of the final implant. (Figure 1) A master-stone-cast was fabricated using mini-implant analogues after taking an impression (Figure 2).

When the conventional prosthetic procedure (registration of the bite in wax, wax-up etc.) has been completed, a barium-sulphate-containing resin was administered in preparation for CT-scanning (Figure 3). This diagnostic CT-setup forms the basis for the manufacturing of the final dental superstructure. The fixed CT-template permits an evaluation of aesthetics, function and occlusion. The CT-template was then affixed to the mini-implants with a specially designed screw-complex prior to imaging.

The screw-complex not only stabilizes the CT-template but also compensates for scanning error. CT-images are known to introduce a transfer error of 0.6 mm (standard deviation of 0.4 mm) in the maxilla and one of 0.3 mm (standard



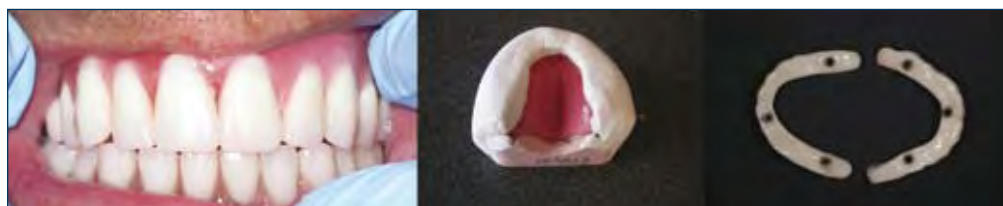**Figure 2** A view of the master stone cast fabricated using mini-implant analogs.

deviation: 0.4mm) in the mandible. The positions of the screws are defined, and are visualized, in CT-images by means of a gutta-percha marker (Figure 4).

Hence the positions of the mini-implants can be identified on the CT-images and adjustments made for errors. The accuracy of the CT measurements depends upon the distance between the virtual cross sections of the images. The position of a mini-implant is determined from the line that runs from its apex to the gutta-percha marker overlying the screws.

The precision of the measurements increases in proportion to the length of the line: as the length of the line increases, the error of 0.3-0.6 mm assumes less significance.

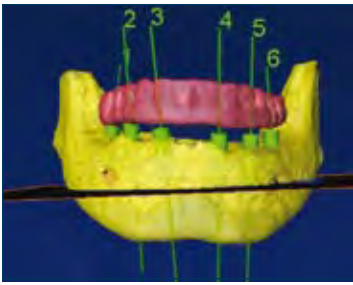
The CT-data were processed to generate multiple cross-sections and 3D-images using the planning software.



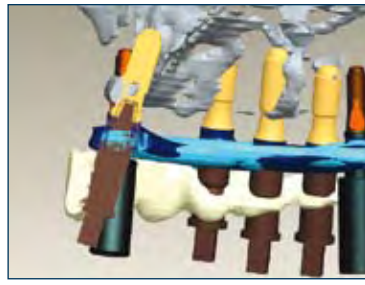
**Figure 3** Views of the wax up and the barium sulfate containing resin scanning guide.



**Figure 4** A view of the screws utilized, with gutta percha markers, for visualization on the CT scan.



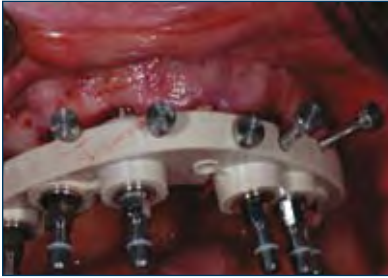**Figure 5** A view of the virtually placed implants.



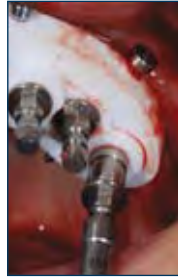**Figure 6** A virtual cross sectional view of the implants and titanium bar of the final prosthesis.




**Figure 7** Views of the frameworks and undersides of the final prostheses.



**Figure 8** The surgical template is secured, and implants are placed.



**Figure 9** Implant insertion is completed.



**Figure 10** The correct depth of implant placement is determined during the virtual planning phase of therapy.

Six Standard Straumann implants per jaw were virtually inserted, taking into account the mass of available bone, the desired dental restoration and underlying anatomical structures (Figure 5). The final dental superstructure perfectly reproduced the scanned barium-sulfate-denture; it was connected to the mini-implants during the CT-imaging process. The planning data was exported to the CAD-software program. The surgical template and the framework of the future dental superstructure were designed using the same planning software data. The imported CT-data and the planned implants are represented as dots in the design software. These dots denote the apex and the top of the implants and thus the orientation and the length of the implants. The design of the template and of the titanium bar of the future superstructure is simplified by the clarity of the barium-sulphate-enhanced image of the diagnostic template. The design software permits cross sectioning in different segments of the diagnostic template which facilitates the delineation of a titanium bar that accords with the available volume of the future prosthesis (Figure 6). The data were imported back to the planning software program in order to virtually check the fit of the planned implants. In this way errors in design can be eliminated before fabrication.

After the planning and the design of the dental superstructure had been approved, the data were sent to the milling company. A simultaneous penta-axial milling device is used for the fabrication of the surgical template and the titanium frameworks. Frameworks were then sent to a dental laboratory to prepare the FDP according to the previous registration using the stone master-casts (Figure 7).

#### Treatment Day

The patients were locally anaesthetized. The surgical template was then connected to the mini-implants. Owing to the good internal connections of the mini-implants and to their triangular distribution, the drilling guide was extremely stable (Figure 8). The drilling sequence for each implant began with punching and terminated with the last drill using, using the template all the time. The implants were then inserted using an implant driver (Straumann, Basel Switzerland), the stop and the guide of which were modified (Figure 9).

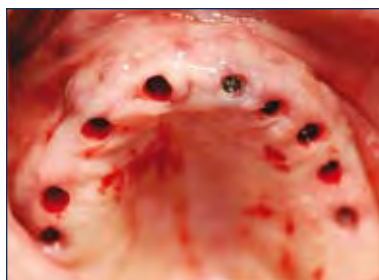Unlike the other available systems, the guiding segment of each drill is of the same diameter, which fits the drilling guide in a very precise manner. The stop on each drill dictates the depth of the osteotomy, which is predetermined during the computer-aided planning of the case. Consequently, no additional instruments are required to

adjust the diameter of each drill, thereby minimizing errors during treatment. Another important improvement that contributes to the higher precision of the implant placement is undoubtedly the so-called precision pin. The hole of the precision pin is in the form of a tunnel, the level of which corresponds to that of the groove in the implant transition driver. The pin emerges only when the implants have been inserted to the correct depth, which is predetermined during the planning of the case (Figure 10). This coincidence in the levels of the groove, tunnel and pin confers not only precision during drilling but also a stabilization of the drilling guide via blockage of the pin. The procedure was repeated for each fixture in the treated jaw (Figure 10).

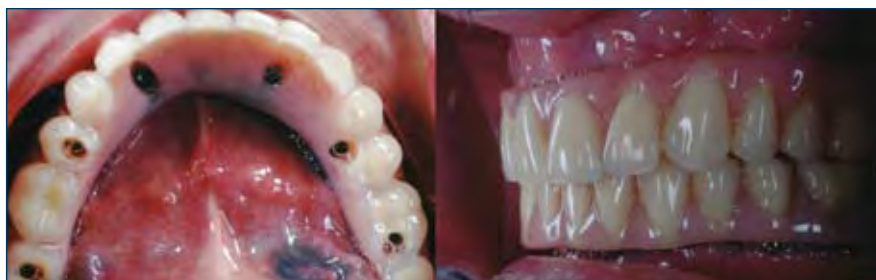After placing of the last implant the surgical template was removed after unscrewing (Figure 11).

Immediately after the implants had been inserted, the dental superstructures were screwed to the implants without the use of interlocking abutments (Figure 12). The mini-implants were removed by reverse torquing. After closing the connection screws the passive fit was evaluated by panoramic radiology (Figure 13).

The occlusion was checked and minor corrections were made in a very short time.



**Figure 11** Following placement of the last implant, the surgical template is unscrewed and removed.

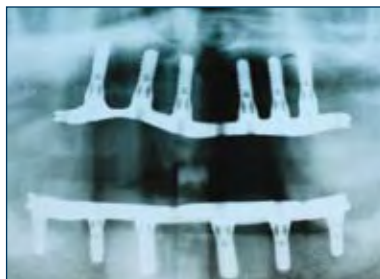


**Figure 12** Views of the dental superstructure screwed to the implants immediately following implant insertion.

### Results

30 patients, 17 males and 13 females between 40-80 years old (average 63 years old) with 34 edentulous jaws have completed their treatment. 199 implants have been inserted and 33 structures have been placed directly on the implants. Three out of 199 implants were lost giving a survival rate of 98.5%. All the superstructures were successful. All the metal frames were produced in the first production run. There was no need to remake any of the individual frameworks prior to the surgery. All milled titanium superstructures (34) showed a satisfactory passive fit at the time of surgery and no adjustments to metal to the implant fit needed to be done.

All the surgeries were carried out following a flapless protocol.



**Figure 13** A panoramic view demonstrates the implant and implant frameworks in place.





**Eduardo R. Lorenzana, DDS, MS** maintains a private practice limited to Periodontics and Dental Implants in San Antonio, Texas. Dr. Lorenzana earned his certificate in Periodontics and a Masters in Oral Biology from Baylor College of Dentistry – TAMUS in Dallas, Texas, and holds an academic appointment there as Adjunct Assistant Professor in the Graduate Periodontics Department. Dr. Lorenzana is a Diplomat of the American Board of Periodontology and has authored scientific papers on oral pathology, oral medicine, and periodontal plastic surgery. He has lectured nationally and internationally on oral medicine, periodontal plastic surgery, restorative-driven dental implant surgery, as well as optimal peri-implant soft tissue esthetics.

## Clinical Review of Minimally Invasive Extraction Techniques


The emergence of dental implant-supported tooth restorations as the treatment of choice in the replacement of missing teeth has resulted in renewed focus on minimally traumatic extraction techniques, particularly in the esthetic zone. Arguably, the removal of the tooth and its accompanying root structure with minimal damage to the alveolar socket is the most pivotal part of any implant-based reconstruction, and facilitates subsequent ridge preservation or immediate implant placement procedures.<sup>1</sup> This fact has led to the introduction of several new instruments of varying designs and costs to help the dentist/implant surgeon more easily accomplish the preservation of the alveolar socket walls, thereby increasing the likelihood of a successful treatment result.

The periotome (G. Hartzell & Son Inc., Concord, CA; Figure 1) is an instrument designed with a sharpened spade- or arrow-shaped tip. It is meant to be positioned into

the periodontal ligament space between the tooth root and the alveolar bone.<sup>2,3</sup> By applying hand pressure to the instrument in the periodontal ligament space, enough separation can theoretically be achieved to facilitate tooth removal and preserve alveolar bone. However, hand pressure alone is often inadequate to position the tip of the periotome deeply enough to provide significant aid in the extraction process. The use of a rubber-tipped surgical mallet (Hu-Friedy, Chicago, IL; Figure 2) is recommended to allow the dentist/surgeon to position the periotome farther apically, facilitating separation of the root from the socket walls (Figure 3). It is important not to attempt to elevate the tooth with the periotome, as its thin blade-like tip is not meant for luxation and can break easily upon improper force application. The tip can be sharpened. Regular re-sharpening is recommended.

The Proximator™ (Karl Schumacher, Southampton, PA; Figure 4) is meant to function in the same manner as a periotome. Due to a sturdier construction, the surgeon is able to elevate the tooth with significantly reduced risk of instrument fracture. With several tip and shank designs to choose from, the Proximator™ instrument line aims to address most clinical situations. As with the periotome, the tips can be sharpened. Use of a surgical mallet for positive seating is also possible (Figure 5). However, due to the larger form of the Proximator®, there is a possibility of causing greater trauma to the alveolar bone.

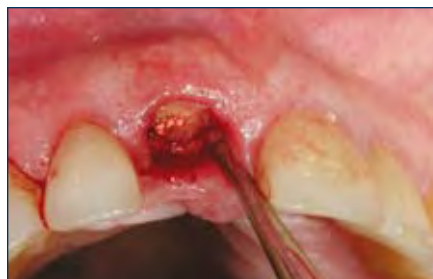The Benex®-Control Root Extraction System (Meisinger USA, LLC, Centennial, CO; Figure 6) allows for minimally invasive extraction of tooth roots when conventional removal with elevators and forceps is not possible; or in the esthetic zone where minimal soft and hard tissue disturbance is desired. The system is




**Figure 1** A close-up view of a periotome tip. (G. Hartzell & Son, Inc.)



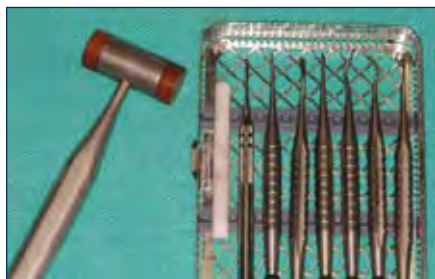
**Figure 2** A view of a nylon-tipped surgical mallet. (Hu-Friedy)



**Figure 3** A clinical view of the periotome in use for extraction of #8. Care must be taken to limit its use to the mesial, distal and palatal aspects of the alveolus, in order to avoid the risk of fracture of the buccal plate, or soft tissue damage.



**Figure 4** A close-up view of the Small Straight Proximator™. (Karl Schumacher USA)



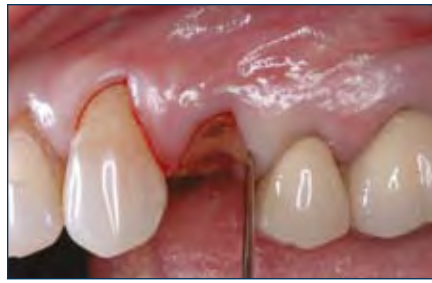**Figure 5** An elevator kit: periotome, set of 6 Proximators™, sharpening stone, and surgical mallet.



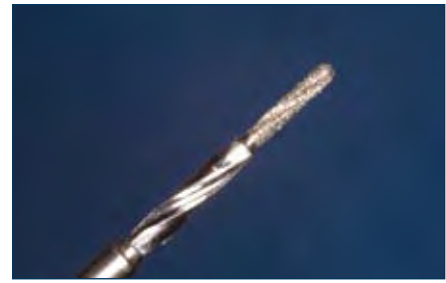**Figure 6** A view of the Benex®-Control Root Extraction System. (Meisinger USA, LLC)



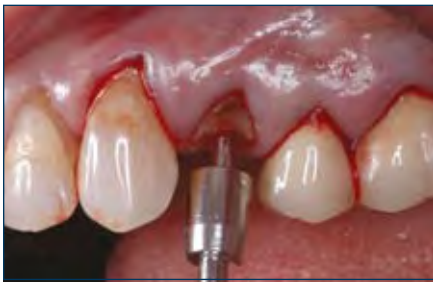**Figure 7** A view of the Benex®-Control Root Extraction System Extractor. Note the white Teflon® pads used to protect the adjacent teeth, and the handscrew knob used to elevate the root. (Meisinger USA, LLC)



**Figure 8** The first step in the use of the Benex®-Control Root Extraction System to extract a fractured tooth #12: a periodontal probe is used to sever the periodontal ligament attachment, followed by gentle luxation.



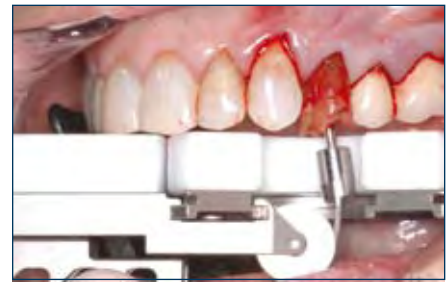**Figure 9** A close-up view of the diamond-tipped twist drill used to prepare the root for the extraction screw.



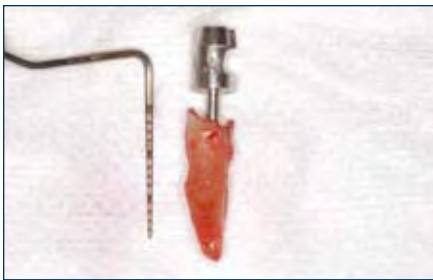**Figure 10** The extraction screw is in position.



**Figure 11** The traction string is in position, engaging both the extraction screw and the extractor.



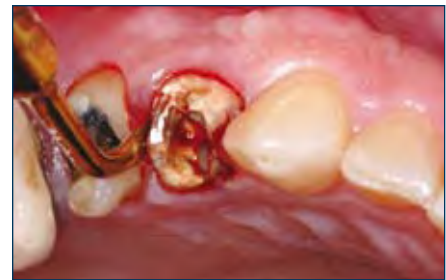**Figure 12** The successful extraction of tooth #12 has been accomplished. Note the separation of the two parts of the extraction slide, and the use of the clinician's finger to maintain control of the traction string and the tooth as it is elevated.



**Figure 13** The root has been removed. Note the undercuts in the root surface.



**Figure 14** A close-up view of Piezosurgery® extraction tips: EX1, EX2, EX3.



**Figure 15** The Piezosurgery® tip EX1 is in position during the flapless removal of tooth #5.

keyed around the Extractor (Figure 7), which utilizes a pulley system and controlled traction to elevate and extract tooth roots. The process (Figures 8-13) involves separation of the root and alveolar bone with a periodontal probe with gentle luxation, followed by the use of a twist drill to prepare at least a 7 mm deep channel in the root, into which an extraction screw is inserted. The traction string is hooked into the extraction screw, guided over the pulley and placed into the extraction slide. Once the extractor is in position, tooth extraction takes place by slow, controlled turning of the handscrew. The system works best for single-

rooted teeth, although it can also be used on multi-rooted teeth after sectioning and separation of the roots. Care must be taken when using adjacent periodontally weakened teeth for support. In addition the extraction screw cannot engage the roots properly if the canals have been over prepared.

The Piezosurgery® system (Piezosurgery Inc, Columbus, OH) is described as a “piezoelectric knife” that utilizes tuned piezoelectric technology combined with multiple tips to provide control in the cutting of bone, while minimizing soft tissue damage.<sup>4</sup> Among its

many indications are endodontic surgery, bone chip/bone block harvest, periodontal osseous surgery, implant site preparation, ridge splitting, sinus elevation, distraction osteogenesis, and tooth extraction. The tips utilized for minimally traumatic tooth extraction are the EX1, EX2, and EX3. They are thin and easy to advance into the periodontal ligament space (Figure 14). Torquing of the tips to help elevation is not recommended. Copious irrigation is necessary to avoid heat damage to the bone. Soft tissue-sparing piezo technology makes this instrument a useful part of the implant surgeon's armamentarium,

resulting in a significant reduction in soft tissue morbidity.<sup>5,6</sup> Elevation and delivery of the tooth are accomplished with the subsequent use of Proximators™ or the Benex®-Control device.

## Conclusions

Immediate implant surgery, is gaining in prevalence as success rates continue to rival conventional implant therapy.<sup>7</sup> Regardless of whether a clinician wishes to employ a staged approach to implant placement or immediate implant placement, an intact socket greatly increases the chances of success; and in the esthetic zone, esthetic success. The aforementioned instruments and devices are not meant to supplant the use of the tried-and-true armamentarium of conventional elevators and forceps. They have, however, been shown to provide significant help in challenging situations, esthetic and otherwise.

## References

1. **American Academy of Periodontology. Tooth extraction during the course of periodontal therapy.** *J Periodontol* 2003;74:933.
2. Thomson PJ. **Minimising trauma in dental extractions: the use of the periotome.** *Br Dent J.* 1992;7;172(5):179.
3. Levitt D. **Atraumatic extraction and root retrieval using the periotome: a precursor to immediate placement of dental implants.** *Dent Today.* 2001;20(11):53-7.
4. Vercellotti T, Nevins ML, Kim DM, Nevins M, Wada K, Schenk RK, Fiorellini JP. **Osseous Response following Resective Therapy with a Piezosurgery®.** *Int J Periodontics Restorative Dent.* 2005; 25(6): 543-549.
5. Vercellotti T, De Paoli S, Nevins M. **The piezoelectric bony window osteotomy and sinus membrane elevation: introduction of a new technique for simplification of the sinus augmentation procedure.** *Int J Periodontics Restorative Dent.* 2001;21(6):561-7.
6. Wallace SS, Mazor Z, Froum SJ, Cho SC, Tarnow DP. **Schneiderian membrane perforation rate during sinus elevation using piezosurgery: clinical results of 100 consecutive cases.** *Int J Periodontics Restorative Dent.* 2007;27(5):413-9.
7. **Proceedings of the Third ITI (International Team for Implantology) Consensus Conference. Gstaad, Switzerland, August 2003.** *Int J Oral Maxillofac Implants.* 2004;19 Suppl:21-22.





**Steven I. Present, DMD** is a graduate of the University Of Wisconsin and Temple University School of Dentistry. He did postgraduate studies in microbiology and immunology at Thomas Jefferson Medical College and completed a program for the treatment of oral facial pain and temporomandibular disorders at The New Jersey College of Medicine and Dentistry. Dr. Present lectures on advanced and complex implant reconstruction.

## Guided Wound Healing – Trans-mucosal Development in the Esthetic Zone

The development and appearance of the trans-mucosal region as the tooth emerges into the oral cavity can mean the difference between treatment failure and success. In order to optimize our chances for a successful treatment outcome, we must base our clinical protocols on sound biologic principles and an understanding of the effects our procedures have on wound healing and tissue repair.

The emergence profile is defined as the contours of the restoration as it emerges through the soft tissues to form the clinical crown.

This profile supports the pericoronal soft tissues (free gingival margins and papillae) and is a critical factor in determining esthetics, and ultimately the difference between success and failure of our restorations. A primary goal in the development of soft tissue contours is predictable long-term stability. In order to achieve this end, the biology of wound healing must be understood and managed.

The evolution of surface technology from a smooth machined surface to the hydrophilic

SLActive® has significantly reduced the time of osseointegration.

However, this is not the case with soft tissue. Trans-mucosal development is the guidance of the healing of the pericoronal tissues to the desired shape and dimensions for proper support, and mimicing as closely as possible of the pericoronal tissues of the contralateral tooth.

Healing can be defined as the body's replacement of destroyed tissue by living tissue. There are two components of soft tissue healing, regeneration and repair. In regeneration, tissue is replaced by the proliferation of surrounding undamaged specialized cells. During repair, lost or damaged tissue is replaced by granulation tissue, which matures to form a scar. As illustrated in Figure 1, there are four phases of tissue repair: bleeding, inflammation, proliferation, and remodeling. They are not mutually exclusive and overlap.

### Bleeding Phase

1. Relatively short lived
2. Normal bleeding time will vary with the nature of the injury and the tissue. More vascular tissues will bleed for a longer time.
3. The time between injury to the end of bleeding is a few hours.

### Inflammatory Phase (Figure 2)

1. Essential for tissue repair.
2. Rapid onset (few hours). Increases in magnitude for 2-3 days before gradually resolving over a few weeks.
3. A complex, chemically mediated amplification cascade is responsible for initiation and control of the inflammatory reaction.
4. Vascular and cellular cascades are the two essential elements. They occur parallel to each other and are interlinked.

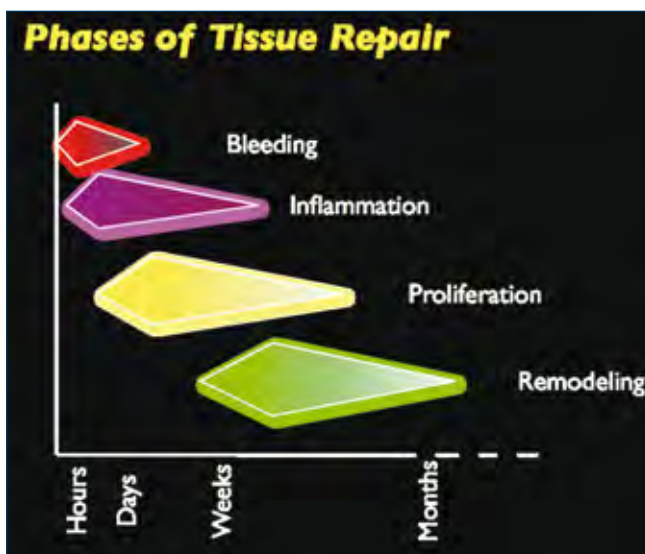


Figure 1 The four phases of tissue healing.

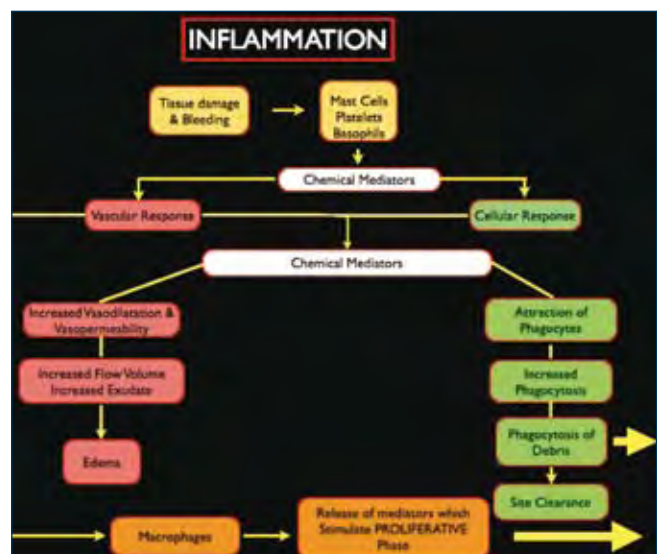


Figure 2 The sequences of the Inflammatory Phase.

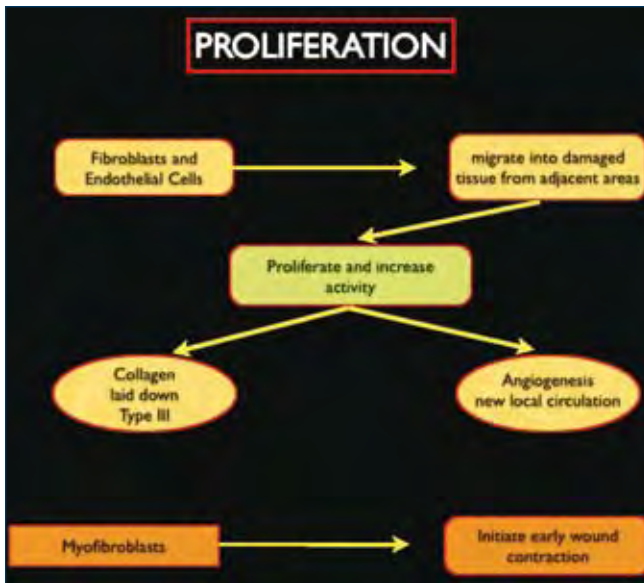


Figure 3 The sequences of the Proliferation Phase.

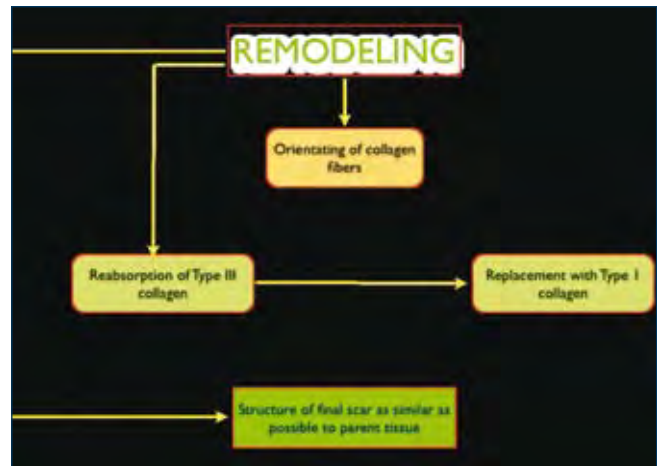


Figure 4 The sequences of the Remodeling Phase.

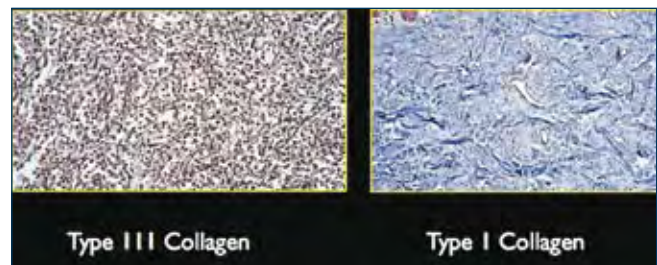


Figure 5 The histologic appearance of collagen. Note the greater density and organization of type 1 collagen.

Due to histamine, vasodilatation causes an increase in blood flow and complement cascade components C3 & C5. White blood cells migrate, platelets adhere to vessel walls and endothelial cells swell, resulting in an increase in vasopermeability. Combined with increase blood flow, this results in increased exudates, including plasma proteins, due to histamine. Serotonin (5-HT), bradykinin, leukotrienes are all potentiated by prostaglandins. Mast cells release hyaluronic acid, which binds with the exudate to create a gel which limits flow. Cellular components include early neutrophil emigration from vessels, followed by monocytes, lymphocytes, eosinophils, basophils. Polymorpho-nuclear leukocytes (PMN) act as early debriders. An end product of phagocytosis is lactic acid, which is a stimulus of Proliferation, the next sequence.

### Proliferation Phase (Figure 3)

1. Involves generation of repair material
2. Rapid onset, 24 – 48 hours
3. Peak activity reached in 2 – 3 weeks
4. Decreases over several months
5. Two fundamental processes: fibroplasia and angiogenesis

6. Chemical mediators (i.e. Macrophage Derived Growth Factors, Platelet Derived Growth Factor, Lactic Acid, Fibroblast Growth Factor)

### Remodeling Phase (Figures 4, 5)

1. Primarily involves collagen and the extra-cellular matrix
2. With maturity collagen becomes oriented more in line with local stresses
3. Type III collagen which is fine, weak and highly cellular (it is the collagen of granulation tissue and produced by young fibroblasts) is converted to Type I collagen, which is more cross linked with greater tensile strength, and is more stable.

Although wound healing involves the four stages previously listed, factors that can have an adverse influence on healing and are known to cause its delay include age, protein deficiency, low vitamin C levels, use of steroids and NSAID's, and low temperature. Local factors include poor blood supply and ischemia, adhesion to bone or other underlying tissues, continued inflammation, drying of the wound, and excessive movement.

Proper wound healing cannot occur without inflammation. The production of prostaglandins plays an essential role in this process. Does the use of NSAID's effect wound healing? Animal studies indicate a delay in the repair of damaged tissues including decreased collagen concentration, decreased bone healing, and decreased bone to implant contact. However, these studies are small and equivocal. Large prospective studies are needed. Another question to be investigated is "if a patient is only on an NSAID for a short period of time is there a negative clinical effect on wound healing?" A corollary to this question would be "is there anything that can be done to accelerate soft tissue healing?" One of the prime initiators of both hard and soft tissue healing is Recombinate-Human Platelet-Derived Growth Factor BB, a potent activator of mesenchymal cells which stimulates chemotaxis, proliferation and new gene expression in monocytes, macrophages and fibroblasts. Incision wound studies have shown that rh-PDGF BB augmented wound strength by 50% and accelerated wound closure by 30% over the first three weeks. Additional animal and human studies demonstrate dramatically enhanced re-epithelization and prevention of wound contracture with rh-PDGF BB use.

In order for an implant supported crown to be esthetic it must be in harmony with the perioral facial structures of the patient and imitate the natural appearance of the missing dental unit(s) in color, form, texture size, and optical properties. This result is dependent upon proper submucosal positioning in all three dimensions, long term stability of esthetic and peri-implant soft tissue contours and symmetry of clinical crown volumes between the implant restoration and the contralateral teeth.

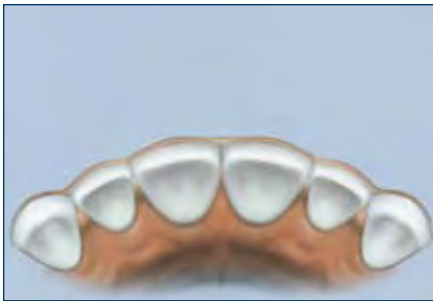Teeth in the anterior maxilla have a triangular cross sectional shape as they emerge into the oral cavity. Dental implants are circular (Figure 6). In order to establish the proper emergence profile, support the peri-implant and optimize treatment outcomes, provisional

restorations are used to guide healing and shape soft tissues prior to delivery of definitive restorations. However, immediate sites are managed differently than sites that are healed and mature. When fabricating an immediate provisional restoration, subgingival contours should be slightly concave to encourage excessive tissue development. With a mature healed site, the proliferation phase of the healing process is already complete. Therefore provisional restorations can be contoured as necessary to develop the desired final contours.

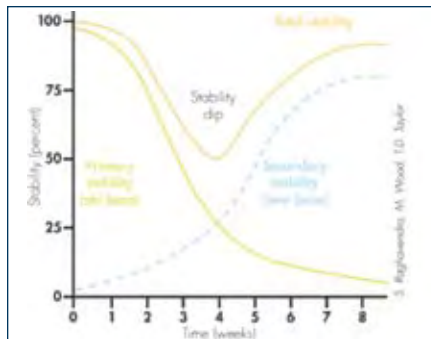
Raghavendra's Implant Stability Curve (Figure 7) demonstrates the need for provisional restorations to be placed within the first week of implant placement and left alone for at least four weeks. This timetable coincides

with the completion of the proliferation phase (Figure 8). At 4 weeks the contours of the provisional restorations can be adjusted. If final impressions are made prior to the near completion of the remodeling phase, the peri-implant tissues will be immature. In such a situation, final results and the long term stability of the final restorations will not be as well controlled.

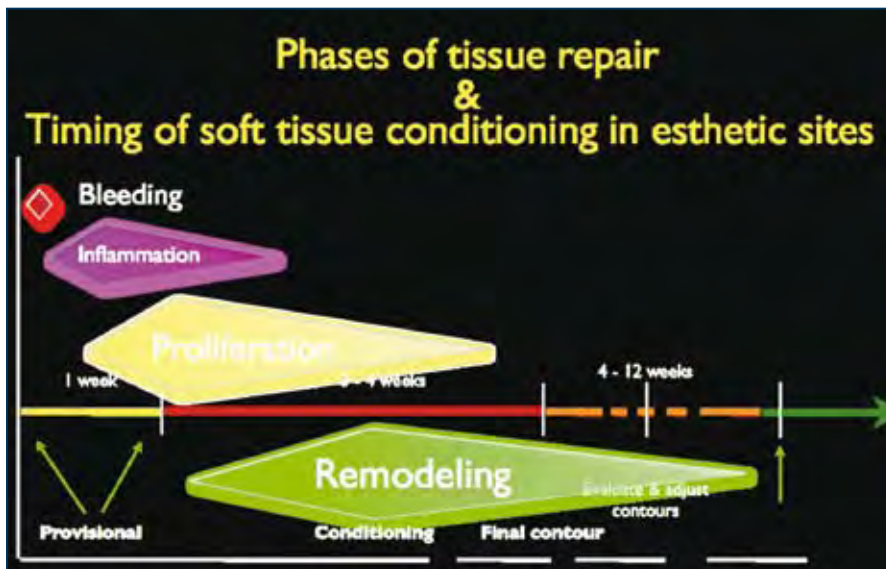
Once final tissue contours and the transmucosal zone have been established, that information must be communicated to the laboratory technicians. This is accomplished with custom impression copings. There are various techniques for their fabrication, one of which is illustrated in Volume 1 of the ITI Treatment Guide.



**Figure 6** A comparison of tooth shape as it emerges into the oral cavity to that of dental implants.



**Figure 7** The implant stability curve.



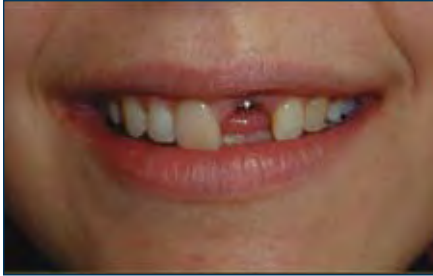**Figure 8** The timing of developing the final contours of provisional restorations should correspond to the later stages of the remodeling phase of tissue healing.

### Case 1: A Healed Site (Figures 9-16)

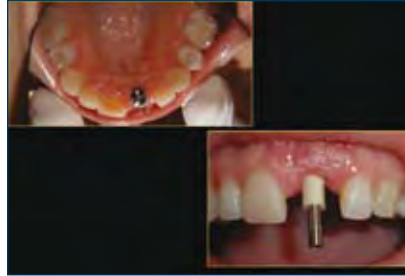A 27 year old female was referred for restoration of tooth #9. The implant was placed by her periodontist approximately five to six months previous. Her medical and dental history were unremarkable and she was wearing a Hawley retainer with a tooth as a provisional restoration. A mesial-

distal size discrepancy was noted, where the edentulous space #9 was slightly greater than #8. This problem was to be corrected with the placement a direct composite on #10. As this was a mature healed site, a screw retained provisional restoration was fabricated with the estimated ideal contours to sculpt the trans-mucosal zone. The patient was recalled every two weeks to evaluate the soft tissue architecture. Adjustments to

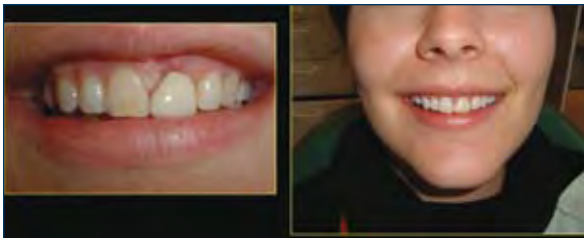
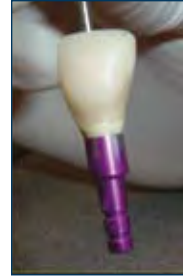
the provisional restoration were made as necessary to establish the desired shape of the free gingival margin and interdental papillae. Once the desired contours were established, an additional two weeks was allowed before the final impression was made. A three year follow up demonstrated excellent stability of the trans-mucosal zone, while maintaining the desired heights of the free gingival margin and papillae.



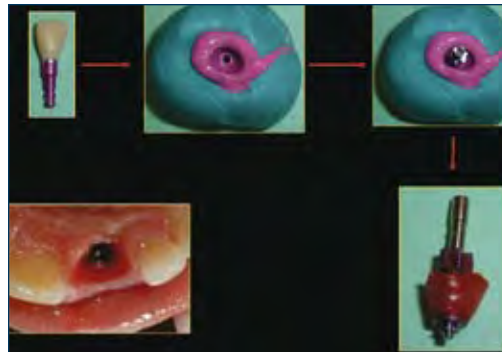**Figure 9** A patient upon presentation. Observe the size discrepancy between the implant site and tooth #8.



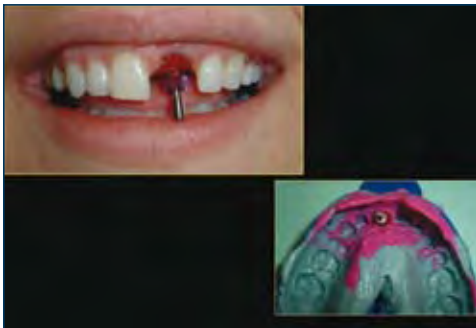
**Figures 10, 11** Fabrication of the provisional restoration is carried out.



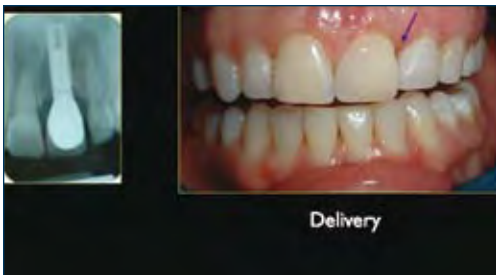**Figure 12** The provisional restoration is in place.



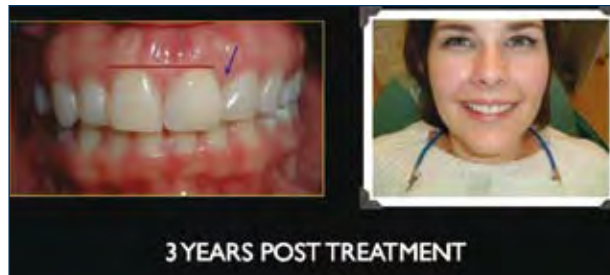**Figure 13** Fabrication of the open tray custom impression coping, in order to capture and communicate the anatomy of the trans-mucosal zone to the laboratory technician, is carried out.



**Figure 14** A custom impression coping is in place, supporting and maintaining the developed emergence profile.



**Figure 15** A view of the restoration at delivery. Note the distal papilla is not filling the space.



**Figure 16** A view of the restoration at three years. Note the filling in of the distal papilla and the maintenance of the facial marginal gingival.

## Case 2: An Immediate Site (Figures 17-25)

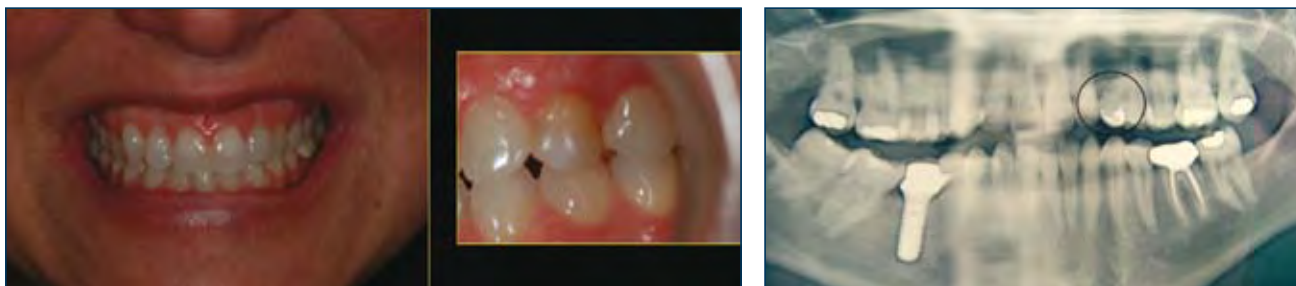A thirty five year old female presented with a failing retained left primary canine. Tooth #11 was congenitally missing. Her medical and dental histories were unremarkable, except for the replacement of tooth #30 with a Straumann tissue level implant in 1998. The patient refused orthodontic therapy to align her anterior dentition. A surgical stent was fabricated from a diagnostic wax up to facilitate surgical placement of the implant in the proper three dimensional position (Figure 19). Immediately following implant placement surgery, the patient had a screw retained provisional restoration fabricated. The provisional restoration was under contoured to allow development of a slight excess of peri-implant soft tissue in the trans-mucosal zone. The provisional restoration was coated

with Polysporin® ointment upon placement, and chlorhexidine 0.12% rinse was prescribed. A screw retained provisional restoration was used to avoid the possibility of residual cement which would compromise healing, and to facilitate future fabrication of a custom impression coping. After approximately four weeks, to allow adequate time for near completion of the proliferation phase of healing, the patient was recalled. Adjustments were begun to the contours of the provisional restoration, to develop an ideal emergence profile to support free gingival margins and inter-dental papillae. After approximately eleven weeks of additional healing (fifteen weeks post surgery) the healing process had progressed to a point to allow a final impression to be taken. A custom impression coping was fabricated and the impression was made. Two year follow up shows maintenance of the free gingival margin and inter-dental

papillae. However, the free gingival margin is not at the ideal apical position. The surgeon stated that the surgical stent was not utilized. Although the implant was placed in good mesial-distal and facial-palatal positions, it was not placed far enough apically to position the facial gingival margin at the same level as tooth #11 (Figure 24). Fortunately, the patient has been satisfied with the final results.

## Discussion

Predictability and stability should be goals of all implant supported restorations. In order to achieve these goals, the peri-implant tissue must be given an adequate amount of time to develop and mature. Therefore, the clinician must understand the stages of wound healing and time restorative procedures accordingly.



Figures 17, 18 A patient as she presented with a failing left primary canine.

Patient _____			
IMPLANT ESTHETIC RISK PROFILE			
Esthetic risk factors	Low	Medium	High
Medical status	Healthy patient and intact immune system		Reduced immune system
Smoking habit	Non-smoker	Light smoker < 10 Cig/D	Heavy smoker > 10 Cig/D
Patients esthetic expectations	Low	Medium	High
Lip line	Low	Medium	High
Gingival biotype	Low scalloped Thick	Medium scalloped Medium thick	High scalloped Thin
Shape of tooth crowns	Rectangular	Slightly triangular	Triangular
Infection at implant site	None	Chronic	Acute
Bone level at adjacent teeth	≤ 5mm to contact point	5.5 to 6.5mm to contact point	7mm to contact point
Restoration status of neighboring teeth	Virgin		Restored
Width of edentulous span	1 tooth ≥ 7mm	1 tooth ≤ 7mm	2 teeth or more
Soft tissue anatomy	Intact soft tissue		Soft tissue defects
Bone anatomy of alveolar crest	No bone deficiency	Horizontal bone deficiency	Vertical bone deficiency

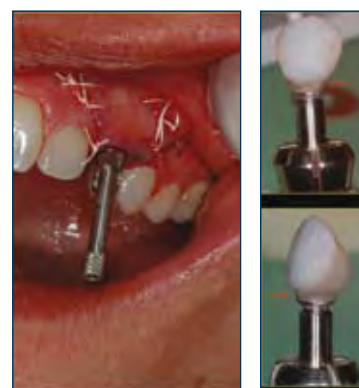
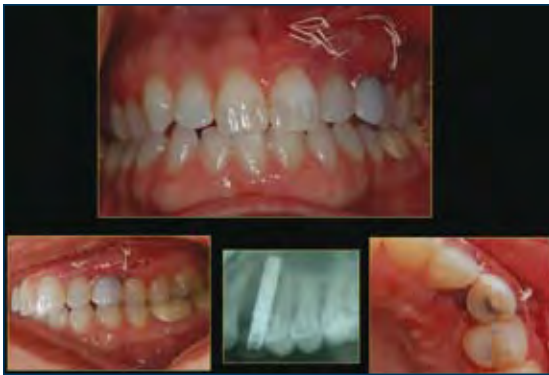
Figure 20 Fabrication of screw retained provisional restoration is carried out immediately following surgery.

Figure 19 Due to high lip line, triangular teeth, and thin tissue but with no other significant modifying factors, the patient is a medium risk.



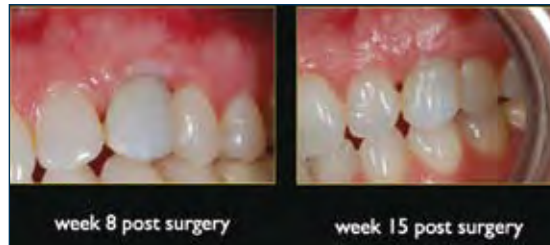**Figure 21** The provisional restoration is in place.



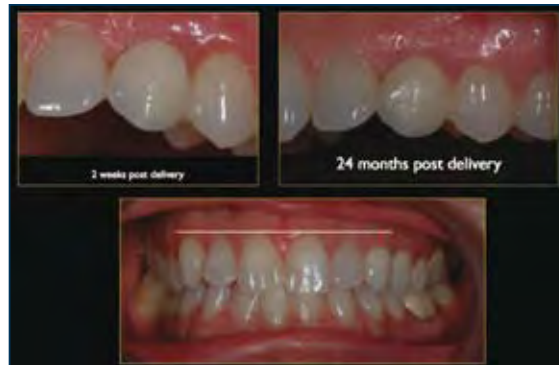**Figure 23** Fabrication of the open tray custom impression coping is carried out.

## References

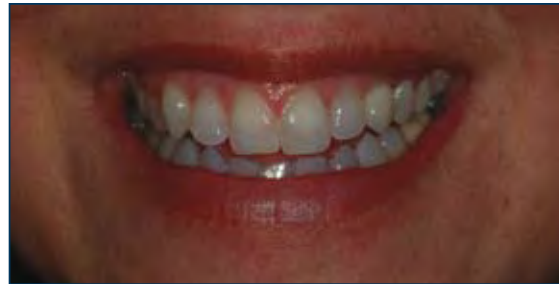1. Belser U et al. *ITI Treatment Guide Vol. 1. Quintessence Publishing Co. 2007 Ltd*
2. Ibara L et al. *Braz Dent J 2007;13:92-96*
3. Busti AJ et al. *Pharmacotherapy 2005;25*
4. Komsu AJ. *IADR Conf. 2006*
5. Pablos AB et al. *J. of Periodontology Online 2008*
6. *Adam North Guy's and St. Thomas Medical Information Service 2006*
7. Gaichi I et al. *JOMI 2008;23:835-840*
8. Pierce CF Dept. of Experimental Pathology, Amgen Inc.
9. Hom DB et al. *Facial Plastic Surgery 2002; 18:41-52*
10. Saba A. *Annals of Plastic Surgery 2002;49: 62-66*
11. *3rd ITI Consensus Conference 2003*
12. Walter JB and Israel MS. *General Pathology 1987; Churchill Livingstone*
13. Hardy MA. *Biology of Scar Formation, Physical Therapy 1989;69:1014-1024*
14. Ryan GB et al. *Acute Inflammation: A Review. Am J. Pathology 1977;86:184-276*



**Figure 22** Note the development of final contours during the remodeling phase.



**Figures 24, 25** The final restoration is in place. Note the height discrepancy of the facial gingival margin as compared to tooth #11. However gingival contours have remained stable at 24 months.





**Paul A. Fugazzotto, DDS** received his DDS from New York University in 1979 and a certificate of advanced graduate studies in Periodontology from Boston University in 1981. Since that time Dr. Fugazzotto has maintained a private practice limited to periodontics and implant therapy in Milton, Massachusetts. Dr. Fugazzotto has published over 85 articles in refereed journals, and two textbooks entitled "Preparation of the Periodontium for Restorative Dentistry" and "Regenerative and Implant Therapies: A Guide to Decision Making". Dr. Fugazzotto is an active member of many organizations including the American Dental Association, the American Academy of Periodontology, and the Academy of Osseointegration. He is a Fellow of the International Team for Implantology, and a senior editor of *Implant Realities*.

## The Use of Shorter Implants in Clinical Practice

The positive effects of a shorter crown to root ratio on the prognoses of teeth in various clinical scenarios has been well documented, as have the potential deleterious effects of a longer crown to root ratio on the prognoses of both individual teeth and treatment outcomes as a whole.

Crown to root ratio is often seen as an indicator of the presence or absence of loss of supporting bone around tooth roots due to periodontal disease and/or other factors. Normally proportioned teeth exhibit a greater crown to root ratio as periodontal disease progresses, and the supporting bone is lost. The lever arms of functional and parafunctional forces are also increased following loss of supporting bone. These are the two primary reasons crown to root ratio is cited as a prognosticator of prognosis.

Conversely, a crown to root ratio within the "normal" range of 0.60 for maxillary teeth and 0.55 for mandibular teeth is not an indicator of periodontal health, or an assurance that periodontal bone destruction has not occurred around a given tooth in the past. Should a patient exhibit a parafunctional habit which results in excessive loss of tooth structure of the anatomical crown, in conjunction with periodontal bone loss around the root of the tooth, the crown to root ratio may fall within a "normal" range. In addition, a reduced crown to root ratio demands that the clinician examine the patient for potential parafunctional habits and excessive tooth wear.

When osseointegrating implants were introduced to the dental community, an assumption was made that longer implants (i.e., implants with a greater surface area for potential osseointegration) would prove more advantageous, and present with a superior long term prognosis when compared to shorter implants, in most if not all clinical situations. Early publications documenting the extensive use of machined screw Branemark implants seemed to bear out this belief.<sup>1-4</sup> It is important to note that the osseointegrating implants documented in these studies were machined screw, hex headed implants placed in a countersunk manner.

If success rates are attainable which are comparable to those of their longer counterparts, shorter implant use will help the clinician avoid vital structures, including the sinus floor and the inferior alveolar canal. The use of shorter implants will often eliminate the need to perform augmentation therapy. Even when augmentation therapy is still necessary, the extent of augmentation required will be significantly decreased.

However, before advocating the utilization of shorter implants in various situations, it is important to examine the available finite element analyses and clinical data. Only if shorter implant use may be grounded in a biomechanical rationale, and reinforced by available clinical data, should the conscientious clinician consider shorter implant use as routine therapy which does not represent a compromise to the patient.

### Finite Element Analyses

Lum<sup>5</sup> utilized finite element analysis to examine the distribution of occlusal forces placed on implants to the surrounding bone, and found that occlusal forces were distributed primarily to the crestal bone, regardless of implant length. While such masticatory forces were well tolerated by the crestal bone, parafunctional forces were not, leading Lum to state that parafunctional forces must be attenuated.

Pierriesnard et al<sup>6</sup> performed a finite element analysis on 3.75mm wide hex headed screw implants of lengths of 6, 7, 8, 9, 10, 11 and 12 millimeters, and found that the magnitude and distribution of bone stress was constant, and was independent of implant length.

Lai et al<sup>7</sup>, performed finite element analysis on 3.75 mm wide 10 mm long, hex headed implant cylinders under thirty-five Newton centimeters of vertical load to the implant cylinders, and found the greatest stress was concentrated at the neck of the implant. Peak stress was independent of implant length, and was inversely proportional to the extent of osseointegration.

Holmgren et al<sup>8</sup> performed a finite element analysis of stepped and straight press fit

implants, and found that implant length had no effect on either peak stress magnitude or stress distribution. Stress was concentrated at the bone crest regardless of implant length.

Himmlova et al<sup>9</sup> found during a finite element analysis of implants in mandibular molar positions the greatest force concentration upon force application was always at the bone crest, and stated that wider diameter implant use decreased peak stress levels at the bone crest.

Many more finite element analyses have been carried out to examine stress distribution following force application to implants in various areas of the mouth. The preponderance of finite element analyses come to common conclusions:

- The greatest magnitude of stress is always found at the bone crest, at the bone implant interface.
- Peak stress is independent of implant length.
- Occlusal stresses (forces) are better tolerated than parafunctional stresses (forces).

### Clinical Studies

Studies most frequently quoted to support the need for longer implants document success and failure rates for smooth surfaced, screw type, hex headed implants.<sup>1-4</sup> Buser et al reported no difference in longer and shorter implant success rates in an eight year life table analysis of 2359 titanium plasma sprayed Straumann implants.<sup>10</sup>

Feldman et al<sup>11</sup> examined five year survival rates of 2294 rough surface Osteotite implants, and 2597 smooth machine surfaced implants. The difference in cumulative success rates between shorter and longer rough surface implants was 0.7%, while the difference in cumulative success rates for smooth versus rough surface implants was 2.2%. Implant surface must be considered in the decision to utilize shorter implants.

Domingues das Neves et al<sup>12</sup> collated the results of thirty three studies of 16,344 "Branemark type" implants, to assess success

and failure rates over time. Of the 786 failures in these studies (4.8%), implant length could not be correlated with implant success or failure, with one exception. 3.75 mm wide x 7 mm long, smooth surfaced, hex headed, counter sunk screw implants demonstrated the highest failure rate (66.7%) when placed in "poor quality" (i.e. type IV) bone, as would be expected.<sup>13</sup>

A publication assessing the clinical results of 5526 Straumann implants documented use of implants of different lengths in a variety of clinical applications.<sup>14</sup> The implants were followed for up to 72 plus months in function. The mean time in function was 32 plus months. Implant length had no influence on the reported cumulative success rates.

Anitua et al<sup>21</sup> reported a cumulative success rate of 99.2% for 532 implants of up to

7-8.5mm in length, after a mean time in function of thirty-one months.

Despite the plethora of articles which demonstrate success rates with shorter implants comparable to their longer counterparts<sup>15-19</sup>, the literature quoted is not yet convincing. In the studies considered, the patients could have been reconstructed at a reduced vertical dimension, resulting in a crown to root ratio more in line with the "ideal" numbers postulated by Wheeler in the natural dentition (i.e. 0.60 for maxillary teeth and 0.55 for mandibular teeth). It is therefore critical to assess the available literature regarding the influence of crown to implant ratio on implant success and failure rates. Rokni et al<sup>20</sup> examined 199 implants, 5 to 12mm in length, which had been restored with fixed prostheses. Mean crown to implant ratio was 1.5. The implants were in function

for an average 4 years. Neither crown to implant ratio nor implant length had any effect on the supporting bone levels around the implants.

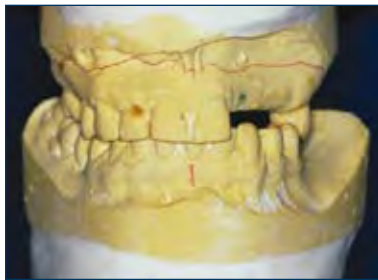Tawil et al<sup>21</sup> assessed 262 machined surfaced Branemark implants in function for a mean time of 53 months, and found no relationship between crown to implant ratio and either peri implant bone loss, or implant success and failure rates.

Blanes et al<sup>22</sup>, in a ten year prospective study of ITI implants in the posterior maxilla, reported a cumulative success rate of 94.1% for 192 ITI implants restored with crown to implant ratios between 2 and 3.

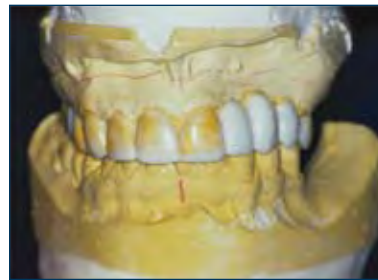In situations where significant ridge resorption has occurred, extensive vertical ridge augmentation procedures and placement of longer implants in an effort to better idealize the crown implant ratio, has long been believed to be necessary. Is such an approach still warranted?

**Table 1**

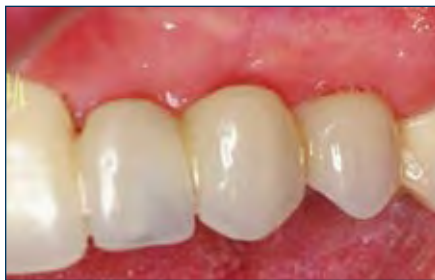Global Prerequisites of Successful Implant Utilization
Appropriate Examination, Diagnosis, and Case Work-up
Development of a Comprehensive Treatment Plan
Amelioration of Parafunctional Forces
Regenerative Therapy as Necessary to Ensure Ideal Implant Size and Position



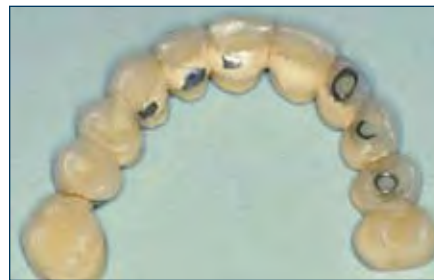**Figure 1** Face-bow mounted models demonstrate the maxillary hard and soft tissue deficiencies which must be managed if appropriate implant reconstructive therapy is to be carried out.



**Figure 2** A diagnostic wax-up has been performed on the face-bow mounted models. The wax-up will now be cut back to the desired level so that a temporary prosthesis may be fabricated which will serve as a regenerative guide.



**Figure 3** Following regenerative therapy, hard and soft tissues have been rebuilt to the desired levels, in anticipation of implant placement and restoration.



**Figure 4** A metal frame provisional fixed prosthesis has been in place for approximately 17 months. Note that the prosthesis serves multiple functions, including stabilization of the occlusion, provision of teeth for function, and as a guide for both regenerative therapy and implant placement.

### Preconditions for Shorter Implant Use

The conditions which must be present for shorter implant use are no different than those which are mandated for implant therapy in general (Table 1) and are as follows:

- An appropriate diagnosis and case work up must be carried out, so that a comprehensive treatment plan may be formulated. While it is possible that a patient who presents with nothing more than a single fractured maxillary incisor, and an otherwise intact dentition with no periodontal or occlusal concerns, may require nothing more than clinical and radiographic examination prior to immediate implant therapy, such a situation is the exception rather than the rule.

When patients demonstrate a greater degree of dental pathology, whether it be carious, periodontal, endodontic, orthodontic, or occlusal, or a combination of a number of these factors, they must undergo a thorough examination and assessment, including facebow mounted models. Periodontists, restorative dentists, laboratory technicians, and other treating dental specialists are then able to examine these models, in conjunction with clinical photographs and the information gleaned from their clinical examinations,

to formulate a comprehensive, unified treatment plan which addresses the patient's specific needs and desires.

Failure to do so will result in less than ideal treatment outcomes (Figures 1 to 4).

- Parafunctional forces must be recognized and ameliorated through appropriate equilibration and/or reconstructive therapy and appliance utilization. Failure to manage parafunctional forces will lead to significant bone loss and increased implant failure, regardless of implant length.
- Regenerative therapy must be performed as necessary. Extensive ridge resorption is often encountered in areas where shorter implant placement is contemplated. Such resorptive patterns seldom proceed in a wholly apical direction. Rather, there is almost always concomitant buccal and lingual/palatal ridge resorption and thinning of the ridge. While it may be possible to place shorter implants in these narrowed ridges, either with generation of minor dehiscences, or with no resulting dehiscences but thin (less than 2mm wide) buccal and/or lingual/palatal residual bony plates, such scenarios cannot be deemed stable, regardless of implant length. There is no reason to expect thin, sometimes translucent, alveolar bone to withstand functional forces and maintain itself over time on the buccal or lingual/palatal aspects of implants.

### A Paradigm Shift

The decision process regarding the need for, and extent of regenerative therapy should proceed as follows:

It is crucial to regenerate adequate alveolar ridge width for placement of ideal diameter implants in prosthetically driven positions. Placement of an implant narrower than one which would ideally be chosen for replacement of a given tooth in an ideal prosthetic position, due to alveolar ridge resorption, is a significant compromise with regard to long-term treatment outcomes. Because forces applied to implants are distributed primarily to the crestal bone, the implant diameter is crucial to appropriate amelioration of these forces.

A patient demonstrates an atrophic ridge in the area of the maxillary central incisor, where implant placement and restoration are anticipated (Figure 5). Available treatment options include:

- Placement of a narrower implant in a somewhat palatal position, angled toward the buccal. A connective tissue graft would be performed to improve the esthetic profile, and the implant would be restored. While such an approach would address the patient's needs and desires in the short term, the net result of therapy would be an implant of a less than ideal diameter, placed in a palatal position, and subjected to off axial forces during function.
- Appropriate regenerative therapy utilizing particulate material and a titanium reinforced membrane to rebuild lost alveolar bone in the region, thus allowing placement of an ideal diameter implant in perfect prosthetic position. This therapeutic approach would afford a greater implant bone surface area at the osseous crest, to help bear force during function, and would eliminate off axial forces.

Regenerative therapy is performed to rebuild damaged alveolar bone in the region. Six months post regenerative treatment, passive primary closure has been maintained (Figure 6). Flap reflection demonstrates regeneration of an ideal ridge form, in anticipation of placement of the appropriate diameter implant in a perfect prosthetic position (Figure 7).

### Assessing the Need for Regenerative Therapies

- The ideal implant diameter for the tooth to be replaced is determined.
- The ideal position for the selected implant is determined.
- A comprehensive patient work-up elucidates the clinical steps which must

be taken to attain such positioning of appropriate diameter implant (ridge augmentation therapy, orthodontics, etc.) to ensure at least 2 mm of bone remains on the buccal and lingual/palatal aspects of the implant after placement.

- The necessary pre-implant placement therapies are carried out.
- The appropriate diameter implant is ideally positioned.
- The implant is subsequently restored.

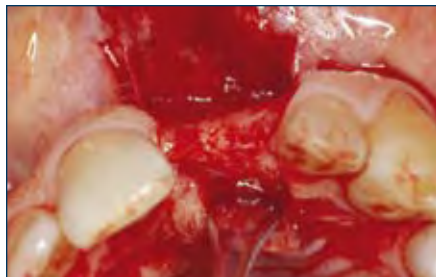It is only through such an approach that long-term treatment outcomes may be maximized.

Hsu et al<sup>23</sup> performed finite element analyses on implants at loading angles of 0, 30 and 60 degrees. Each 30 degree increase in off angle loading increased stresses to the bone crest three to four times. Placement of narrower implants at off angles, and their esthetic restoration through surgical and restorative wizardry, represents a significant compromise for the patient.

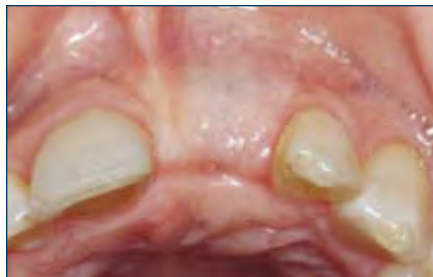### Implant Characteristics to Maximize Prognosis

Regardless of clinicians' allegiances to various implant companies, the available data and common sense demonstrate that implants should present with specific characteristics to maximize the available bone for the attainment of osseointegration, and to contribute to predictable long term implant success. Such considerations include (Table 2):

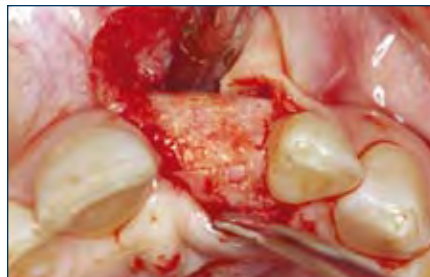- A roughened implant surface: Numerous authors have documented the superior degree of osseointegration and the greater pull out and back torque strengths of rough surface implants when compared to their smooth surface counterparts. It is difficult to find a rationale for the use of smooth surface implants in today's clinical practice.



**Figure 5** Bone atrophy is evident in the maxillary central incisor position.



**Figure 6** Months after regeneration therapy has been performed, soft tissue primary closure has been maintained.



**Figure 7** Flap reflection demonstrates regeneration of lost alveolar bone, and re-establishment of an ideal ridge form.

**Table 2**

Implant Prerequisites for Successful Utilization
Roughened Implant Surface
Internal Abutment Attachment
Appropriate Neck Diameter for the Tooth to be Replaced

**Table 3**

Cumulative Implant Success Rates for Standard Neck Short Implants Restored as Single Crowns in the Posterior Mandible					
Months After Abutment Connection	Implants Beginning of Interval	Failures During Interval	Interval Failure Rate	Cumulative Failure Rate	Cumulative Success Rate
0-12	315	5	1.6	1.6	98.4
13-24	275	0	0	1.6	98.4
25-36	240	0	0	1.6	98.4
37-48	165	0	0	1.6	98.4
49-60	74	0	0	1.6	98.4
61-72	23	0	0	1.6	98.4
73-84	13	0	0	1.6	98.4

**Table 4**

Cumulative Implant Success Rates for Short Implants Utilized as Abutments for Fixed Prosthesis in Posterior Mandible					
Months After Abutment Connection	Implants Beginning of Interval	Failures During Interval	Interval Failure Rate	Cumulative Failure Rate	Cumulative Success Rate
0-12	229	3	1.3	1.3	98.7
13-24	181	0	0	1.3	98.7
25-36	156	1	0.6	1.9	98.1
37-48	110	0	0	1.9	98.1
49-60	70	0	0	1.9	98.1
61-72	20	0	0	1.9	98.1
73-84	7	0	0	1.9	98.1

- Internal vs. external attachment implants: Meada et al<sup>24</sup> applied 30 Ncm of vertical and horizontal load to implants with internal or external hex connections. They reported increased strain at the cervical area with external hex fixtures, as compared to their internal hex counterparts. Meada et al also found that the load was better distributed around internal hex implants than around external hex implants. These findings have been documented by a number of authors in both finite element analyses and histologic animal studies.
- An implant with an appropriate neck diameter should be utilized for replacement of a given tooth: The argument that the use of a wider implant with a wider neck diameter would result in the need for buccal ridge augmentation therapy is not valid, as augmentation therapy should be performed if needed. In a situation with an atrophic buccal ridge, shorter implant use will simplify augmentation therapy, allowing the clinician to perform only a buccal ridge

augmentation procedure instead of buccal and vertical augmentation therapy. As already discussed, the implant body width and neck dimension should be chosen in consideration of the tooth to be replaced, not the width of available residual bone. Once the appropriate implant dimension is selected, augmentation therapy is performed as needed to ensconce the implant in bone of adequate dimensions (at least 2mm) to withstand functional forces over time.

#### **Clinical Applications of Shorter Implant Use**

Straumann implants of 6, 7, 8 and 9 mm in length will be considered short implants. These measurements represent the roughened surface of the implant, and do not include the polished implant neck.

#### **Shorter Implant Use in the Posterior Mandible**

Three hundred and fifteen standard neck ITI implants were placed in atrophic posterior

mandibular areas, and followed for up to 84 months in function, with a mean time in function of 36.2 months.<sup>25</sup> Four implants were mobile at uncover, and one implant was lost during the first twelve months of function, yielding a cumulative success rate of 98.4%. Implant size and duration of time in function are noted in Table 3.

The actual cumulative success rate of the shorter implants in function over this mean time of 36.2 months was 99.7% when the four implants mobile at uncover are excluded, as implants mobile at uncover cast no reflection up on the ability or inability of shorter implants to withstand functional forces over time.

Shorter implants are routinely utilized to replace missing mandibular posterior teeth with abutments and single crowns.

Two hundred twenty nine standard diameter, standard neck Straumann implants were utilized to restore 114 fixed prostheses in mandibular posterior regions (Table 4). One hundred thirteen of these prostheses were three unit prostheses made up of two

**Table 5**

Cumulative Implant Success Rates for Short Wide Platform Implants Restored with Single Crowns in the Posterior Mandible					
Months After Abutment Connection	Implants Beginning of Interval	Failures During Interval	Interval Failure Rate	Cumulative Failure Rate	Cumulative Success Rate
0-12	722	1	0.1	0.1	99.9
13-24	578	0	0	0.1	99.9
25-36	416	0	0	0.1	99.9
37-48	246	0	0	0.1	99.9
49-60	93	0	0	0.1	99.9
61-72	20	0	0	0.1	99.9

implant crowns and a pontic. One prosthesis was a five unit prosthesis made up of three implant crowns with pontics between the terminal abutments and the center implant. The implants were followed for a mean time in function of 40.5 months. Three implants were mobile at abutment connection, and one implant was lost during the 25–36 months in function interval, yielding a cumulative success rate of 98.1%. In Figure 8, a 6 mm long standard neck Straumann implant serves as the distal abutment for a fixed bridge, and an 8 mm long standard neck Straumann abutment serves as the mesial abutment for the three unit fixed prosthesis. This prosthesis has been in function for over five years, with no change in bone crest levels around either of the implants.

Utilization of prostheses with reduced occlusal tables bucco lingually, and in the case of terminal abutments mesio distally, to lessen the magnitudes of functional and parafunctional forces when shorter implants are restored, results in less re-attainment of functional occlusal capabilities for the patient following therapy, and must be viewed as a compromise.

A more appropriate approach, assuming it demonstrates an acceptable level of success under function, is to utilize a shorter implant with a wider prosthetic platform, so as to incorporate a crown of appropriate dimensions to ideally replace the function which has been lost.

Utilization of this approach is not limited to 8mm or longer wide platform Straumann implants. Seven hundred and twenty two wide platform Straumann implants of 6 to 8 mm in length were restored with solid abutments and single crowns, and followed for a mean time of 28.5 months in function. Two implants were mobile at abutment connection. No implants were lost during function for up to 72 months, demonstrating a cumulative success rate under function of 99.9% (Table 5). These implants were not only utilized in “protected” situations where either a restored or natural tooth bordered each side of the implant in

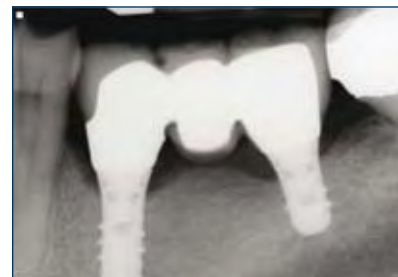
question, but also in terminal molar positions, and were restored with abutments and single crowns (Figure 9).

Implant placement at the time of mandibular molar extraction: Two hundred and eighty three wide platform Straumann implants of various lengths were placed at the time of mandibular molar extraction, and followed for a mean time of 36.4 months in function.<sup>25</sup> Of the 283 implants placed, 204 were 8 or 9 mm in length, and 79 were 10 or 12 mm in length. The mean time in function for the 8 or 9 mm length implants was 36.5 months. The mean time in function for the 10 or 12 mm long implants was 34.7 months. The overall cumulative success rate of these implants in function was 98.7%. The difference between the cumulative success rates for the two groups was not statistically significant (Tables 6, 7).

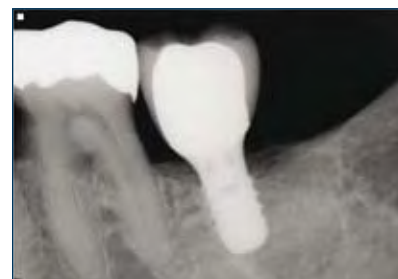Shorter implant utilization in maxillary posterior areas: Nine hundred eighty seven implants replaced missing maxillary molars, and were restored with solid abutments and unsplinted single crowns.<sup>26</sup> The implants were followed for up to 84 months in function, with a mean time in function of 29.3 months, yielding a cumulative success rate in function of 95.1%. Followed to the present day, and including implants placed since initial data compilation, a total of 1757 implants have been placed and restored with solid abutments and single crowns in intact arches, in maxillary molar positions, of lengths between 6 and 12 mm. The cumulative success rate of the implants in function is 95.7%.

Figure 10 demonstrates the stability of the peri implant crestal bone around an 8mm long standard diameter Straumann 84 months after its placement and restoration in a maxillary first molar position.

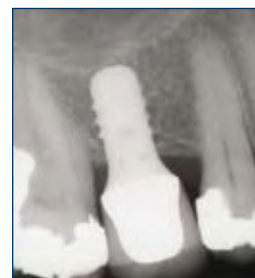Implants of various lengths are often placed in conjunction with trephine and osteotome use to implore a core of the residual bone crestal to the floor of the sinus.



**Figure 8** A 6 mm long standard diameter Straumann implant has been utilized as a terminal abutment for a three unit fixed splint in the mandibular posterior region. A radiograph taken forty-two months after restoration demonstrates peri implant crestal bone stability.



**Figure 9** A radiograph taken seventy-two months after restoration of a wide platform 8 mm long Straumann implant in the position of the mandibular second molar demonstrates stability of the peri implant crestal bone.



**Figure 10** An 8 mm long standard diameter Straumann implant has been restored in a maxillary first molar position. A radiograph taken eighty-four months after restoration demonstrates the stability of the crestal peri implant bone.

**Table 6**

Cumulative Implant Success Rates for Short Wide Platform Implants Placed at the Time of Mandibular Molar Extraction and Restored with Single Crowns					
Months After Abutment Connection	Implants Beginning of Interval	Failures During Interval	Interval Failure Rate	Cumulative Failure Rate	Cumulative Success Rate
0-12	204	1	0.5	0.5	99.5
13-24	153	0	0	0.5	99.5
25-36	113	1	1.0	1.5	98
37-48	94	0	0	1.5	98.5
49-60	52	0	0	1.5	98.5
61-72	23	0	0	1.5	98.5

**Table 7**

Cumulative Success Rates for Wide Platform Implants Placed at the Time of Mandibular Molar Extraction and Restored with Single Crowns						
Implant Length	Months After Abutment Connection	Implants Beginning of Interval	Failures During Interval	Interval Failure Rate	Cumulative Failure Rate	Cumulative Success Rate
8-9 mm	0-12	204	1	0.5	0.5	99.5
	13-24	153	0	0	0.5	99.5
	25-36	113	1	1.0	1.5	98.5
	37-48	84	0	0	1.5	98.5
	49-60	52	0	0	1.5	98.5
	61-72	23	0	0	1.5	98.5
10-12 mm	0-12	79	1	1.3	1.3	98.7
	13-24	72	0	0	1.3	98.7
	25-36	47	0	0	1.3	98.7
	37-48	21	0	0	1.3	98.7
	49-60	8	0	0	1.3	98.7
	61-72	2	0	0	1.3	98.7
TOTAL	0-12	283	2	0.7	0.7	99.3
	13-24	225	0	0	0.7	99.3
	25-36	160	1	0.6	1.3	98.7
	37-48	105	0	0	1.3	98.7
	49-60	60	0	0	1.3	98.7
	61-72	25	0	0	1.3	98.7

Data which examines implants placed in such situations up to the present time, demonstrates that 306 implant 6, 7, 8 or 9 millimeters long, placed at the time of trephine and osteotome use and restored with single crowns, have been in function for up to eight years with a meantime in function of 30.9 months, with cumulative success rate of these implants in function is 99.0%.<sup>27</sup> During the same time frame, the cumulative success rate of 10 and 11 millimeter long implants placed at the time of trephine and osteotome use and restored with single crowns is 98.9%. The difference is not statistically significant.

#### **Shorter implant utilization at the time of maxillary molar extraction**

Two hundred and ninety seven implants were

placed. Two hundred and nine were 10, 12 or 14 millimeters long, and 88 were 8 millimeters long. Mean time in function was 18.9 months. No implants from either group were lost during function.

#### **Conclusions**

Both finite element analyses and available clinical data support the use of shorter implants where advantageous with regard to simplification of therapy and lessening of the time of the overall course of treatment. However, as with any treatment modality, utilization of shorter implants must be grounded in a framework of a comprehensive treatment plan and an understanding of the specific challenges of each patient's care. Severe osteoporosis, the presence of a non-

ideal maxillo mandibular occlusal relationship which cannot be treated through orthodontics and/or surgical correction due to either structural or patient imposed limitations, or the presence of a significant parafunctional habit are all comorbidities which may mandate the use of significant regenerative therapy, longer implants, and possible splinting of implants.

The challenge is not to decide whether or not shorter implants may be successfully utilized in the majority of situations. They may. The challenge facing the conscientious clinician is to identify those situations where such utilization is appropriate, and the instances where other avenues of therapy must be explored.

## References

1. Adell R, Eriksson B, Lekholm U, Branemark P-I, Jemt T. **A long term follow-up study of osseointegrated implants in the treatment of totally edentulous jaws.** *Int J Oral Maxillofac Surg* 1990;5:347-59.
2. Albrektsson T. **A multi center report on osseointegrated oral implants.** *J Prosthet Dent* 1988;60:75-84.
3. Fugazzotto PA, Gulbransen H, Wheeler S, Lindsay J. **The use of IMZ osseointegrated implants in partially and completely edentulous patients: Success and failure rates of 2,023 implant cylinders up to sixty plus months in function.** *Int J Oral Maxillofac Implants* 1993;8:635-40.
4. Albrektsson T, Dahl E, Enbom L, Engevall S, Engquist B, Reiksson AR, Feldman G, Freiberg N, Glantz PO, Kjellman O, Kristersson L, Kvint S, Kondell P, Palmquist J, Werndahl L, Astrand P. **Osseointegrated oral implants: A Swedish multi center study of 8,139 consecutively inserted Nobelpharma implants.** *J Periodontol* 1998;59:287-96.
5. Lum L B. **A biomechanical rationale for the use of short implants.** *J Oral Implantol* 1991;17:126-31.
6. Pierriessard L, Reinouard F, Renoult P, Barquins M. **Influence of implant length and bicortical anchorage on implant stress distribution.** *Clin Impl Dent Rel Res* 2003;5:254-62.
7. Lai H, Zhang F, Zhang B, Yang C, Xue M., **Influence of percentage of osseointegration on stress distribution around dental implants.** *Chin J Dent Res* 1998;1:7-11.
8. Holmgren EP, Seckinger R J, Kilgren LM, Mate F. **Evaluating parameters of osseointegrated dental implants using finite element analysis: A two dimensional comparative study examining the effects of implant diameter, implant shape, and load direction.** *J Oral Implantol* 1998;24:80-8.
9. Himmlova L, Dostalova T, Kacovsky A, Konbickova S. **Influence of implant length and diameter on stress distribution: A final element analysis.** *J Prosthet Dent* 2004;1:20-5.
10. Buser D, Mericske-Stern R, Bernard J, Behneke A, Behnek EN, Belser U, Lang N. **Long term evaluation of non submerged ITI implants.** *Clin Oral Implants Res* 1997;8:161-72.
11. Feldman S, Boitel N, Weng D, Kohles SS, Stach RM. **Five year survival of short machined surface/osteotite implants.** *Clin Impl Dent Rel Res* 2004;6:16-23.
12. das Neves FD, Fones D, Bernardeds SR, do Prado CJ, Neto AJ. **Short implants – an analysis of longitudinal studies.** *J Oral Maxillofac Implants* 2006;21:86-93.
13. Jaffin RA, Berman CL. **The excessive loss of Branemark fixtures in type IV bone: A 5 year analysis.** *J Periodontol* 1991;62:2-4.
14. Fugazzotto PA, Vlassis J, Butler B. **ITI implant use in private practice. Clinical results with 5,526 implants followed up to 72+ months in function.** *Int J Oral Maxillofac Implants* 2004;3:408-412.
15. Deporter D, Watson P, Pharoah M, Levy D, Todescan R. **Five to six year results of prospective clinical trials using the Endopore dental implant and a mandibular overdenture.** *Clin Oral Implants Res* 1999;10:95-102.
16. ten Bruggenkate CM, Asikainen P, Foitzik C, Krekeler G, Sutter F. **Six millimeter non-submerged dental implants: Results of multicenter clinical trial of 1 to 7 years.** *J Oral Maxillofac Implants* 1998;13:791-98.
17. Nedir R, Bischof M, Briaux J-M, Beter S, Smukler-MONcler S, Bernard J-P. **A seven year life table analysis from a prospective study on ITI implants with special emphasis on the use of short implants. Results from a private practice.** *Clin Oral Impl Res* 2004; 15:150-57.
18. Arlin ML. **Short dental implants as a treatment option: Results from an observational study in a single private practice.** *Int J Oral Maxillofac Implants* 2006;21:769-76.
19. Anitua, E, Orive G, Aguirre JJ, Andia I. **Five year clinical evaluation of short dental implants placed in posterier areas: A retrospective study.** *J Periodontol* 2008;79:42-48.
20. Rockni S, Todescan R, Watson P, Pharoah M, Adegbembo AO, Deporter D. **Assessment of crown to root ratios with short sintered porous surface implants.** *Int J Oral Maxillofac Implants* 2005; 20:69-76.
21. Tawil G, Aboujaoude N, Younan R. **Influence of prosthetic parameters on the survival and complication rates of short implants.** *Int J Oral Maxillofac Implants* 2006;21:275-82.
22. Blanes RJ, Bernard JP, Blanes ZM, Belser VC. **A ten year prospective study of ITI implants in the posterior maxilla: Influence of crown implant ratio.** *Clin Oral Implants Res* 2007;18:707-14.
23. Hsu M-L, Chen F-C, Kao H-C, Cheng C-K. **Influence of off access loading on an anterior maxillary implant: A three dimensional finite element analysis.** *Int J Oral Maxillofac Implants* 2007;22:301-09.
24. Meada Y, Satoh T, Sogo M. **In vitro differences of stress concentrations for internal and external hex connections.** *J Oral Rehabil* 2006;33:75-8.
25. Fugazzotto PA. **Implant placement at the time of mandibular molar extraction: Description of technique and preliminary results of 341 cases.** *J Periodontol* 2008; 79:737-747.
26. Fugazzotto PA, Beagle J, Vlassis J, Ganeles J, Jaffin R, Kumar A. **Success and failure rates of 987 implants 9 millimeters or shorter replacing missing maxillary molars.** *J Periodontol* 2004;75:327-32.
27. Fugazzotto PA. **Shorter implants in clinical practice: Rationale and treatment results.** *Int J Maxillofac*, 2008; 23:487-496.





**Richard P. Kinsel, DDS** received his dental degree in 1979 from the University of the Pacific School of Dentistry in San Francisco, California. He was Assistant Professor for eight years in the Department of Fixed Prosthodontics at U.O.P. and is currently Assistant Clinical Professor in the Department of Restorative Dentistry, Division of Prosthodontics at the University of California, San Francisco, School of Dentistry. Dr. Kinsel is the Director of Implant Dentistry at the A.E.G.D. Post-Graduate Residency and developed the program's implant curriculum and syllabus. He is an active member of the American Prosthodontic Society, Federation of Prosthodontic Organizations, the Academy of Osseointegration, and an associate member of the American Academy of Periodontology. Dr. Kinsel has published in various journals and presented numerous seminars related to implant dentistry both nationally and internationally. He maintains a private practice in Foster City emphasizing implant and periodontal prosthodontics.

## A Simplified Procedure to Ensure Optimal Gingival Contours for the Single Implant-Supported Crown in the Esthetic Zone

Prosthetic replacement of the missing single maxillary central incisor with an implant-supported crown represents a profound esthetic challenge for the restorative dentist, laboratory technician, and surgeon. In addition to the visual fidelity of color, translucency, contour, and surface texture, the proper soft tissue outline is sacrosanct to the illusion of a natural tooth. The contrast between the uniformly round shoulder of the implant and the tooth's curvilinear cemento-enamel junction is particularly problematic.

An optimal gingival frame surrounding implant-supported restorations is important in completing the illusion of natural teeth in the esthetic zone.<sup>1,2</sup> The osseous architecture surrounding a healthy dentition follows the cemento-enamel junctions (CEJs) of the teeth, which terminate approximately 2 mm apically, with a 3 mm gingival tissue overlay.<sup>3</sup> The apical zenith of the facial gingival outline is located slightly distal to the mid-axis of the maxillary central incisor (Figure 1).<sup>4</sup> Although an implant-supported central incisor crown may closely duplicate the adjacent teeth, if the free gingival margins do not match, visual disharmony ensues and the illusion is lost (Figures 2a-b).

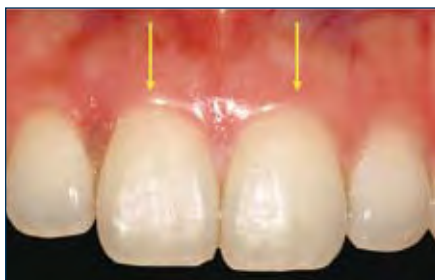It is advantageous to develop the hard and soft tissues of the edentulous site prior to implant placement and restoration.<sup>5</sup> Once this has been accomplished, the surgeon must place the implant in a position that considers the potentially negative influences of the vertical and horizontal components of biologic width.<sup>6-9</sup> Alveolar bone has been shown to resorb approximately 2 mm apically and 1.4 mm laterally to the implant-crown (or abutment) interface. The three-dimensional orientation of the implant coronal platform should preserve the proximal and facial alveolar bone. Excessive apical and facial placement of the implant restorative platforms may lead to bone loss when the physiologic dimensions of biologic width are re-established. As the underlying bone support resorbs, the risk of apical migration of the gingival margin increases. In the one-piece, single-stage implant design, Buser et al have recommended that the implant shoulder be placed approximately 1 mm palatal to the emergence of the adjacent teeth, and 1 mm apical to the CEJ.<sup>10</sup>

Stein and Nevins have cited the importance of the provisional restoration to develop optimal gingival contours for single-tooth implant restorations.<sup>11</sup> The interim crown was used to establish the

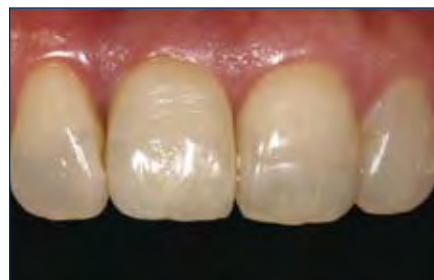desired gingival margin and emergence profile. This information was then transferred to the master cast as a guide for the dental technician during the fabrication of the definitive restoration. Clinicians have documented different innovative techniques using the implant-supported provisional crown to form the optimal gingival frame.<sup>12-16</sup> However, considerable time and effort were required to reproduce the resultant gingival contour to the master cast. Intuitively, the question was asked whether an intervening provisional restoration was necessary to form the definitive facial and proximal soft tissue frame.

The protocol described below ensures optimal gingival contours surrounding the implant-supported maxillary single central incisor crown, and defines a new role for both the provisional and definitive crowns. It is imperative that the restorative dentist and dental technician understand that the outline of the facial gingival margin is dictated by the location of the CEJ relative to the root surface (Figure 3).

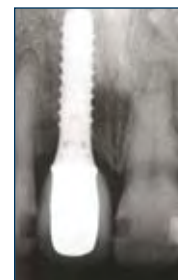A maxillary central incisor tooth that is horizontally sectioned along its long axis reveals the facial-distal prominence near the CEJ (Figure 4). In the presence of adequate soft tissue, duplication of this



**Figure 1** The appearance of a healthy natural dentition demonstrates the harmonious papillary positions and the zenith of the facial gingival margins, slightly distal to the mid-axis of the maxillary incisors.



**Figures 2a, 2b** The facial free gingival margin of the implant-supported maxillary right central incisor crown is uniformly round and lacks the distally inclined apex of the natural tooth, disrupting overall visual harmony.



convexity outline in the definitive crown moves the facial gingiva into a position that emulates the natural dentition. The result is an implant-supported crown that is in visual harmony with the surrounding dentition (Figures 5a-b).

**Clinical Technique**

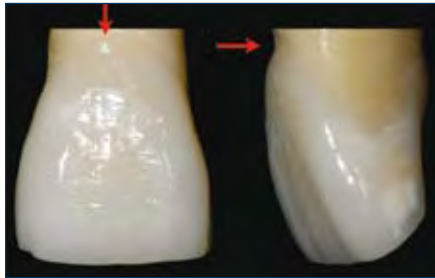
A simplified and precise method of developing optimal gingival contours

that simulate the natural dentition in the esthetic zone is described for restoration of a one-piece, tissue-level implant (Straumann USA, Andover, MA) that was placed in the position of a missing maxillary right central incisor. A connective tissue facial augmentation procedure was performed at implant insertion with an interim removable partial denture serving as the provisional restoration (Figures 6a-b). No attempt was

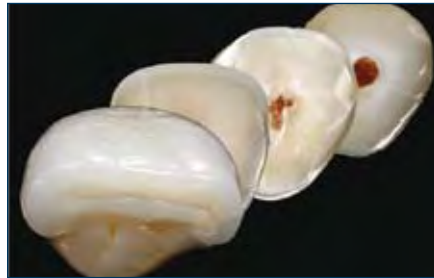made to contour the soft tissues prior to fabrication of the master cast (Figures 7a-b).

A straight abutment (synOcta®, Straumann USA, Andover, MA) was adapted to fit within the contours of the definitive crown using a matrix of the diagnostic wax-up for the metal framework design. Stone was selectively removed from the master cast with a scalpel to simulate the desired gingival facial margin and emergence profile that was harmonious with the adjacent central incisor (Figure 8). The modified cast permitted the ceramist to create the definitive metal-ceramic crown with the CEJ convexity at its prescribed apical position and contour. When the implant coronal platform had been properly placed, the contours of the CEJ and root surfaces of the crowns closely resembled those found in the natural central incisor tooth (Figure 9).

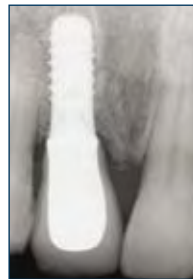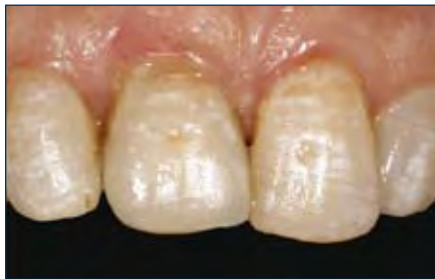The abutment was inserted into the implant and the securing screw was tightened to the torque recommended by the manufacturer (Figures 10a-b). The excessive soft tissue prevented the complete seating of the metal-ceramic crown. Therefore, trial cementation with a



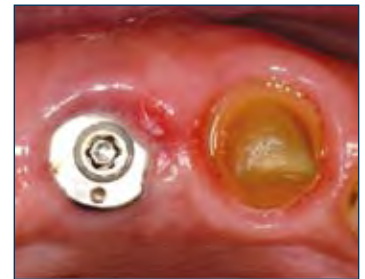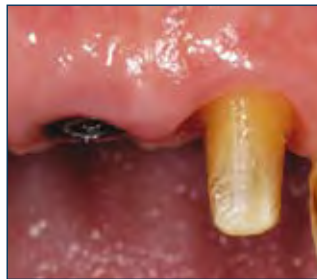**Figure 3** The maxillary central incisor had a curvilinear junction formed by the convexity of the CEJ and the relative concavity of the root surface. The challenge for the implant-supported crown lay in the transition from a flat rotational platform surface to the natural cervical anatomy.



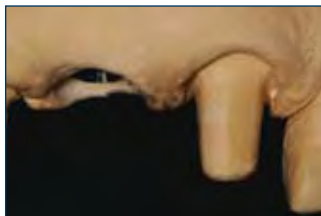
**Figure 4** Transverse sections of the maxillary right central incisor along the incisal-apical axis showed the increased distal-facial prominence of the natural tooth. This resulted in the typical free gingival margin outline.



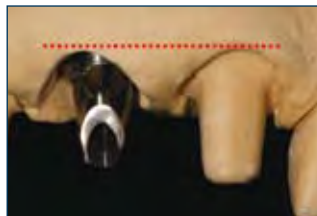**Figures 5a, 5b** A view of the facial gingival contour of an implant-supported, metal-ceramic crown replacing a missing maxillary right central incisor. Note that the gingival margin is in harmony with the adjacent natural central incisor.



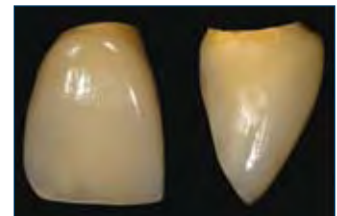**Figures 6a, 6b** The clinical appearance of asymmetrical gingival contours prior to insertion of the definitive metal-ceramic crown. Excessive soft tissue was present in both the facial and coronal dimensions, and there was a lack of optimal papillary height adjacent to the implant.



**Figures 7a, 7b** The tissue-level impression yielded a master cast that duplicated the clinical situation. No attempt was made to modify the soft tissue surrounding the implant.



**Figure 8** The master cast was modified by selectively removing stone to develop a facial gingival margin and emergence profile consistent with the adjacent central incisor tooth.



**Figure 9** The facial and proximal views of the final metal-ceramic crown. Note the defined outline of the CEJ convexity that selectively moves the facial gingival margin into the desired position.

provisional luting agent (i.e., ZONE, DUX Dental, Oxnard, CA, USA) was used for one week. Upon initial seating of the crown, blanching of the adjacent gingiva was evidenced, but dissipated in approximately ten minutes (Figure 11). The one-week follow-up showed the precise positioning of the gingival margin as dictated by the crown form (Figure 12a). In such cases where the implant-supported crown is adjacent to natural teeth that have normal osseous support (Figure 12b), the deficient proximal papillae will generally reform because the connective tissue fibers insert into the dentin coronal to the alveolar bone.<sup>3</sup> The final cementation of the metal-ceramic crown using a glass-ionomer luting agent (Fuji PLUS, GC America, Aslip, IL) was completed at this appointment. The one-year follow-up is shown in Figure 12c. Note the long-term fidelity of the gingival form and maturation of the surface texture that more closely simulates that found surrounding natural dentition.

#### A New Role for the Provisional Crown

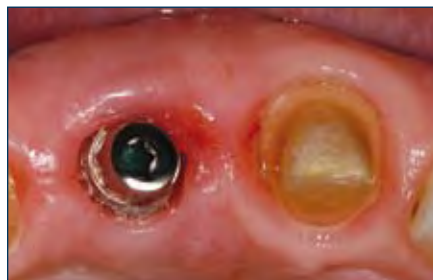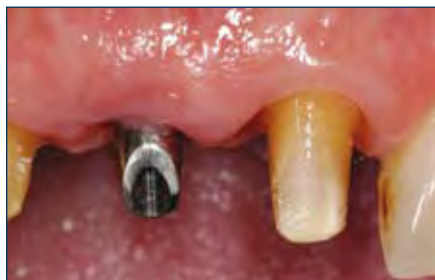Implant site preparation with adequate soft and hard tissue support, combined with proper positioning of the implant

restorative platform, enhances the potential for a successful esthetic result. The provisional restoration, serves the primary purpose of maximizing the volume of surrounding soft tissue both facially and coronally. To facilitate this goal, the CEJ convexity of the provisional restoration is placed more incisal than the desired final gingival margin.

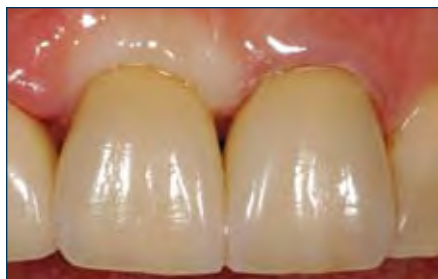In the following case, the implant was placed using a modified tissue punch without flap reflection, which minimized disruption of the surrounding blood supply. The dimension of the soft tissue that was removed to expose the

osteotomy site was less than the outside diameter of the implant's coronal platform. When the tapered neck of the implant was inserted, the crestal keratinized gingiva was displaced in a facial and incisal direction, further increasing the soft tissue volume.

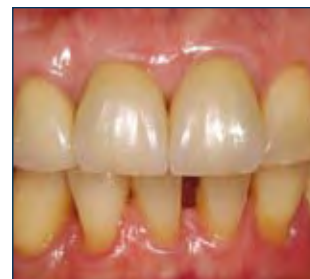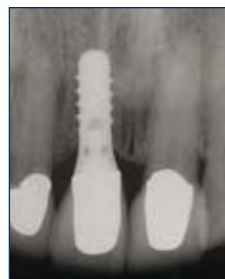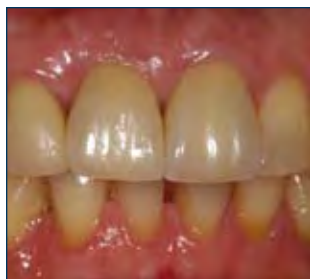A solid abutment was inserted into the implant immediately after surgical placement and the provisional restoration was relined to adapt to both the abutment and the implant platform (Figure 13). The facial contour of the provisional crown was adjusted to promote incisal migration of the soft tissues by increasing the



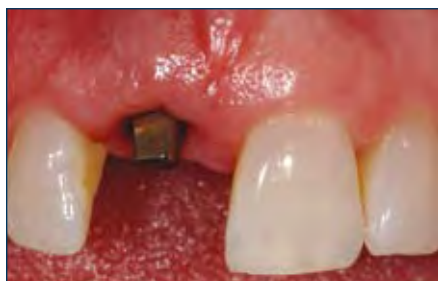**Figures 10a, 10b** The abutment (synOcta<sup>®</sup>, Straumann USA, Andover, MA) was inserted into the implant and secured with the seating screw. Excessive keratinized gingiva could be seen in the facial and occlusal views.



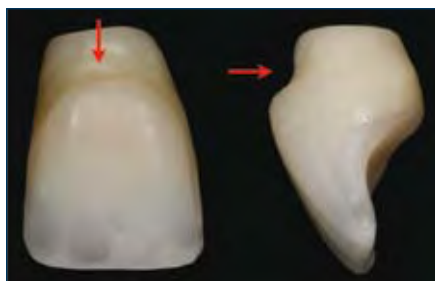
**Figure 11** Trial cementation of the crown using a provisional luting agent compressed the adjacent tissue, causing blanching, which reduced in 10 minutes.



**Figures 12a, b, c** One week postoperatively, the facial gingiva had conformed to the CEJ of the crown (a). A post-operative periapical radiograph demonstrates adequate osseointegration and implant positioning (b). The one-year follow-up shows the long-term stability of the gingival profile (c).



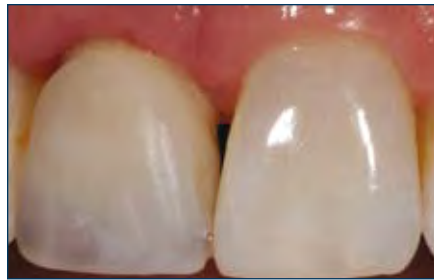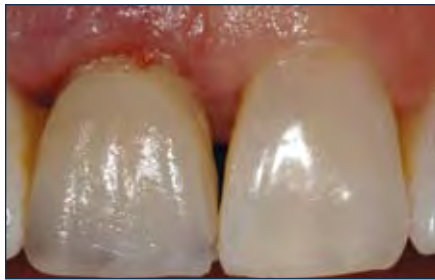**Figure 13** The one-piece, tissue-level implant (Straumann USA, Andover, MA) was placed using a modified tissue punch surgical technique. A 4 mm solid abutment was inserted.



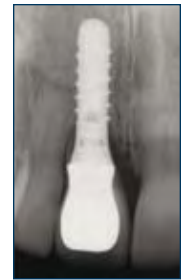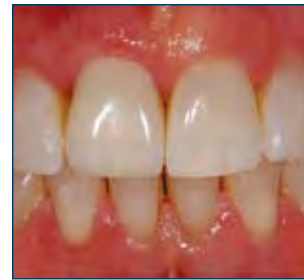**Figure 14** The CEJ convexity outline was placed approximately 1 mm incisal to the desired location in the definitive crown and the root concavity was increased to promote incisal migration of the free gingival margin.

#### Note

The author wishes to acknowledge fellow ITI member Daniele Capoferri, CDT for his consideration and well-appreciated ceramic skills.



**Figures 15a, 15b** The interim restoration was cemented with a provisional luting agent. Initially, the facial and proximal soft tissues were in an apical location (a). Following the six-week osseointegration period, the free gingival margin and the interdental papillae had moved coronally due to the concavity of the provisional crown's root form (b).



**Figures 16a, 16b** A view of the final clinical appearance. The proximal papillae will predictably reform when the alveolar bone of the adjacent teeth provides adequate support for the overlying soft tissue (a). A post-operative periapical radiograph (b).

root concavity apical to the CEJ (Figure 14). The provisional crown was placed immediately and, following the six-week osseointegration period, the facial soft tissue migrated into a more coronal position (Figures 15a-b). The definitive metal-ceramic crown had contours that simulated the left central incisor and molded the free gingival margin into the desired position (Figures 16a-b).

### Conclusions

The successful restoration of the missing single central incisor is a result of the implant team's collaborative skills. Clinicians have previously presented a variety of techniques to create an implant-supported restoration that is in harmony with the surrounding hard and soft tissue. This case presentation describes a simplified method to precisely duplicate the facial gingiva and proximal soft tissue contours for single, implant-supported crowns in the esthetic zone. The new role for the provisional restoration is directed toward increasing the soft tissue volume and subsequent precise movement of the gingival margin using the definitive metal-ceramic crown.

Surgical augmentation and judicious contouring of the provisional restoration are directed toward increasing the surrounding soft tissue volume, not to define the final free gingival margin position. In order to properly modify the master case and emulate the CEJ curvilinear profile of a natural tooth, the restorative dentist and laboratory technician must have a basic knowledge of the crown and root morphology. The definitive metal-ceramic crown, specifically the convexity outline of the CEJ, ultimately determines the gingival frame.

### References

1. Belser UC, Buser D, Hess D, et al. **Aesthetic implant restorations in partially edentulous patients—A critical appraisal.** *Periodontol 2000* 1998;17:132-150.
2. Grunder U, Spielman HP, Gaberthüel T. **Implant-supported single tooth replacement in the aesthetic region: A complex challenge.** *Pract Periodont Aesthet Dent* 1996;8:835-842.
3. Schroeder HE, Page RC. **The normal periodontium.** In: Schluger S, Yuodelis R, Page RC, Johnson RH, eds. *Periodontal Diseases: Basic Phenomena, Clinical Management, and Occlusal and Restorative Interrelationships.* Philadelphia, PA: Lea & Febiger;1990:3-52.
4. Mattos CML, Santana RB. **A quantitative evaluation of the spatial displacement of the gingival zenith in the maxillary anterior dentition.** *J Periodontol* 2008;79:1880-1885.
5. Belser U, Buser D, Higginbottom F. **Consensus statements and recommended clinical procedures regarding esthetics in implant dentistry.** *Int J Oral Maxillofac Impl* 2004;19(Suppl):73-74.
6. Hämmerle CH, Brägger U, Bürgin W, Lang NP. **The effect of subcrestal placement of the polished surface of ITI implants on marginal soft and hard tissues.** *Clin Oral Impl Res* 1996;7:111-119.
7. Hermann JS, Cochran DL, Nummikoski PV, Buser D. **Crestal bone changes around titanium implants. A radiographic evaluation of unloaded nonsubmerged and submerged implants in the canine mandible.** *J Periodontol* 1997;68:1117-1130.
8. Cochran DL, Hermann JS, Schenk RK, et al. **Biologic width around titanium implants. A histometric analysis of the implantogingival junction around unloaded and loaded nonsubmerged implants in the canine mandible.** *J Periodontol* 1997;68:186-198.
9. Piattelli A, Vrespa G, Petrone G, Iezzi G, Annibaldi S, Scarano A. **Role of the microgap between implant and abutment: A retrospective histologic evaluation in monkeys.** *J Periodontol* 2003;74:346-352.
10. Buser D, Martin W, Belser UC. **Optimizing esthetics for implant restorations in the anterior maxilla: Anatomic and surgical considerations.** *Int J Oral Maxillofac Impl* 2004;19(Suppl):43-61.
11. Stein JM, Nevins M. **The relationship of the guided gingival frame to the provisional crown for a single-implant restoration.** *Compend Contin Educ Dent* 1996;17:1175-1182.
12. Paranhos KS, Oliveira R. **An impression technique to accurately transfer soft tissue contours for implant-supported restorations: three case reports.** *J Oral Impl* 2001;27:317-321.
13. Chee WW. **Provisional restorations in soft tissue management around dental implants.** *Periodontol 2000* 2000;27:139-147.
14. Polack MA. **Simple method of fabricating an impression coping to reproduce peri-implant gingiva on the master cast.** *J Prosthet Dent* 2002;88:221-223.
15. Macintosh DC, Sutherland M. **Method for developing an optimal emergence profile using heat-polymerized provisional restorations for single-tooth implant-supported restorations.** *J Prosthet Dent* 2004;91:289-292.
16. Higginbottom F, Belser U, Jones JD, Keith SE. **Prosthetic management of implants in the esthetic zone.** *Int J Oral Maxillofac Impl* 2004;19(Suppl):62-72.



**Will Martin, DMD, MS** is a Clinical Associate Professor in the Departments of Oral and Maxillofacial Surgery and Prosthodontics at the University of Florida's College of Dentistry. He received his DMD with honors from the University of Florida and completed his MS and Certificate in Prosthodontics from Baylor College of Dentistry. Dr. Martin joined the faculty at the University of Florida in 1999 and serves as the Clinical Director of the Center for Implant Dentistry. Dr. Martin is a diplomate of the American Board of Prosthodontics. He is a fellow of the American College of Prosthodontists, International College of Dentists, International Team for Implantology (ITI) and member of numerous professional organizations including the Academy of Osseointegration, ADA and FDA. Dr. Martin's research interests include implant design, loading protocols, and implant biomechanics. He maintains a practice limited to Prosthodontics within the Center for Implant Dentistry. He lectures both nationally and internationally on esthetic and implant dentistry.

## Indications, Planning and Restorative Techniques Utilizing the Bone Level Implant – Preliminary Results from a Multi-Center Clinical Trial

Dentists and patients alike have consistently reaped benefits from advances in dental implant technology for over a decade. These benefits can be expressed through several indicators. Reduction of overall treatment time, rate of osseointegration, longevity of osseointegration, stability of the prosthetic connection and ease of utilization, have improved the overall efficacy of implant therapy. Attention has been directed on the design of the dental implant's prosthetic connection and its position to the crestal bone.

Historically, use of implant designs that position the implant-abutment connection (micro-gap) less than 2mm vertically from the crestal bone has resulted in vertical bone loss.<sup>1-5</sup> It has been reported in several publications that this bone loss can be influenced by various factors: bacterial colonization within the micro-gap, micro-motion of the implant/abutment interface, repeated placement or removal of components and excessive occlusal loads.<sup>1-9</sup> One implant design with a vertical micro-gap offset of 1.8mm has been shown in animal and clinical studies to create a biologically stable environment that minimizes crestal remodeling<sup>1-9</sup> (Figure 1).

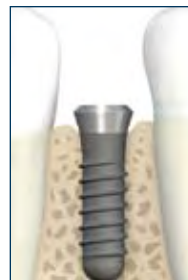These implants, often referred to as soft-tissue level implants have been used with great success in a wide variety of clinical situations. Over the past decade, implant designs that place the micro-gap in a horizontally off-set position from the external surface of the implant have resulted in a decrease in bone remodeling when the implant was placed at the level of the crestal bone.<sup>10-22</sup> The clinical advantages of an implant design that allows positioning at the bone crest can be appreciated with thin biotype patients with high esthetic demands, limited intra- and inter-arch space situations and extended edentulous spaces in the esthetic zone. One clear benefit to this implant design is the

option for submerged or non-submerged healing. While the introduction of new and improved implant design technology is common in today's market, it remains critical to test and evaluate these modifications to determine if they are suitable for the clinical arena and general patient population.

The Straumann® Company recently launched a bone level implant design as an important addition to its dental implant system, to offer an expanded range of treatment options for clinical situations faced in implant practice (Figure 2). The surgical procedures are similar to those for the soft-tissue level implant line, and the prosthetic components, which are slightly different in the design of the connection, offer cemented and screw-retained options. One unique feature of the bone level implant is the CrossFit™ Connection, which provides tactile feedback during seating of components while creating a stable connection at the bone crest. An added feature of this CrossFit™ Connection is its ability to accommodate CAD/CAM design and manufacturing, making it a connection for future innovations.

The following case illustrates the restoration of site #8 with a Straumann® Bone Level Implant and a screw-retained crown using a zirconia dioxide (ZrO2) CAD/CAM abutment and restoration (Figures 3a to 3q).

Prior to the release of the Straumann bone-level implant, several pre-clinical and clinical studies were initiated to test the behavior of the implant when placed in varying clinical situations. Preliminary data from a randomized, controlled clinical study comparing submerged versus transmucosal placement of bone level implants in the anterior maxilla or mandible by evaluation of the change in bone level between first stage surgery and 6 months post-surgery has been reported.



**Figure 1**  
A view of a Straumann® soft-tissue level implant indicating vertical offset of the microgap from the crestal bone.



**Figure 2**  
A view of a Straumann® bone level implant indicating the horizontal offset of the microgap at the crestal bone level.

The principle investigator Professor Christoph Hämmerle, Co-investigators are Sanz M, Chen St, Martin W, Jackowski J, Cordaro L, Ivanoff CJ, Ganeles J, Jung R, Weingart D, Wiltfang J, Gahlert M and Sclar A, participated in this multi-center study.

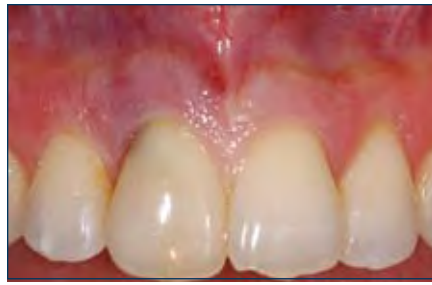This investigation was designed to evaluate the amount of bone level change with submerged (group a) and transmucosal healing (group b), and to assess any difference in bone level changes between the two procedures with Straumann® Bone Level implants. Several additional parameters were measured, including soft-tissue stability and the influence of implant positioning on esthetic outcomes.

The materials and methods for the study were as follows. The treatment indication called for implants to replace single teeth in the anterior region (maxilla or mandible). During the recruitment period, implants were placed in a total of 146 patients in 12 centers in seven countries worldwide. In both groups a provisional restoration was placed on the implant between 8 and 14 weeks.

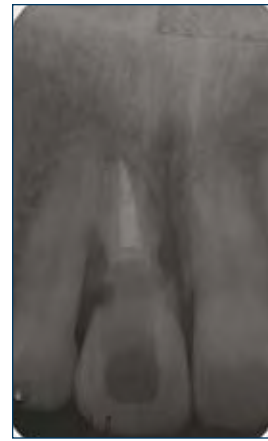The final restoration was delivered after 26 weeks in both groups. Standardized radiographs were taken at the time of surgery (baseline), provisional placement (approx. 14 weeks), final crown placement (6 months) and 12 months. Follow-up is intended each year for up to 5 years.

The interim results as of August 2008 reported that 137 patients had received their provisional restoration, and 133 had received their final restoration. Of these, 69 have been evaluated at their annual 1-year follow-up. No device related serious adverse events have been observed. The mean bone level change from baseline to 6 months was  $-0.29 \pm 0.42$  mm. Bone level change was  $< -0.5$  mm in 74.8 % of cases. The difference in bone level change between the two procedures was  $-0.066$  mm (95 % CI  $-0.22$  to  $+0.09$ ), indicating equivalence of the two procedures. Figures 4a – 5a, highlight a sample of peri-apical radiographs at implant placement and at the one-year post-surgical follow-up visit for both transmucosal and sub-mucosal healing.

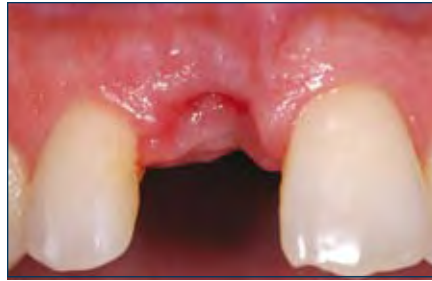The interim conclusions are as follows: Out of 146 implants placed only one implant failure has been noted after 6 months, resulting in a survival rate of 99.3% for Straumann Bone Level implants. Minimal bone loss was observed for both submerged and transmucosal implants. There was no significant difference between submerged and transmucosal healing.



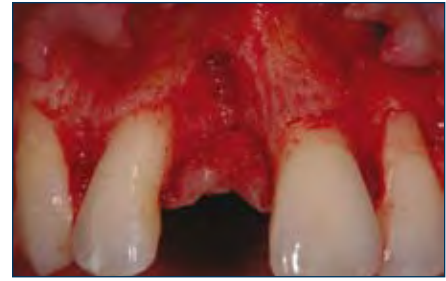**Figure 3a** A pre-treatment frontal view of #8.



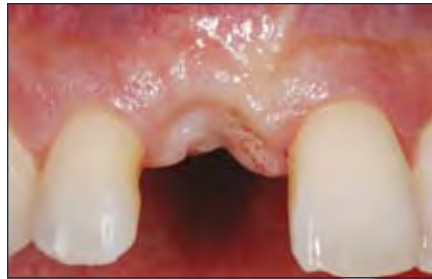**Figure 3b** A peri-apical radiograph of #8, exhibiting internal and external resorption.



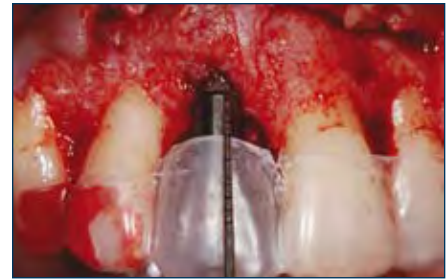**Figure 3c** The frontal view 8-weeks post-extraction of tooth #8.



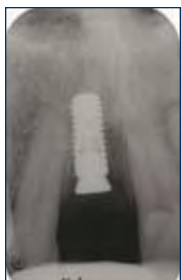**Figure 3d** The frontal view prior to hard tissue augmentation (allograft).



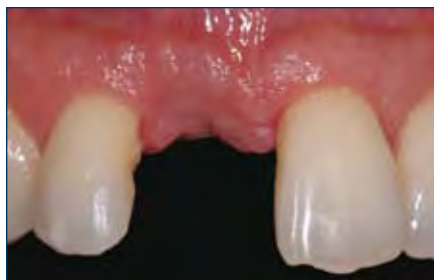**Figure 3e** The frontal view 6-months post-grafting.



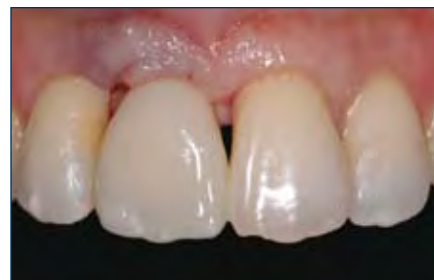**Figure 3f** A view of post-implant placement. The implant is placed 3 mm apical to planned mucosal margin.



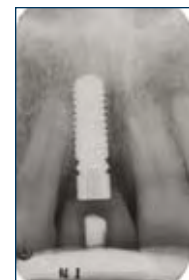**Figure 3g** A peri-apical radiograph following implant placement.



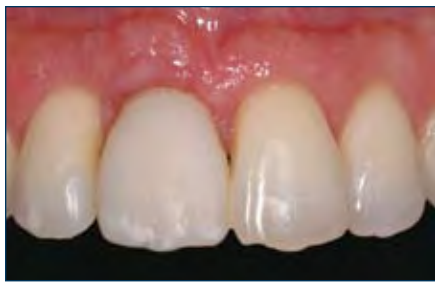**Figure 3h** A frontal view 8-weeks post-placement.



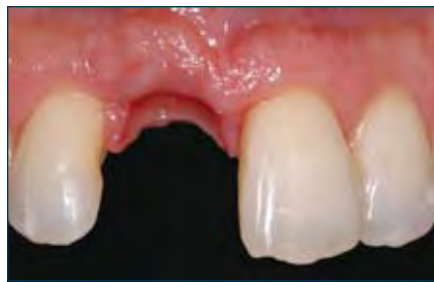**Figure 3i** A frontal view post-loading with a screw-retained provisional restoration.



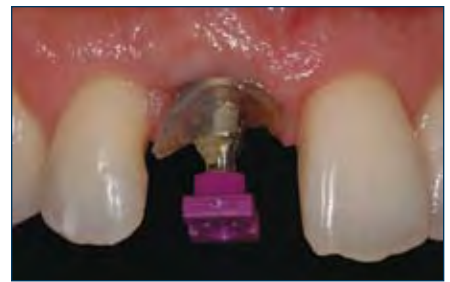**Figure 3j** A peri-apical radiograph post-loading.



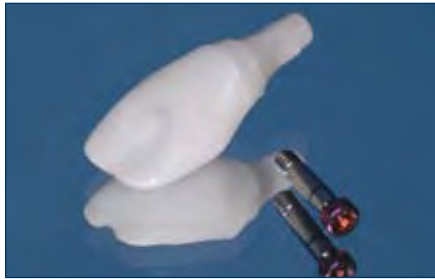**Figure 3k** A frontal view of the provisional restoration 6-weeks post-loading.



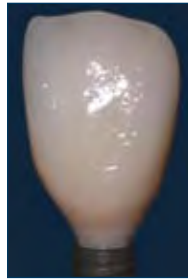**Figure 3l** A frontal view of the soft-tissue transition zone after removal of the provisional restoration.



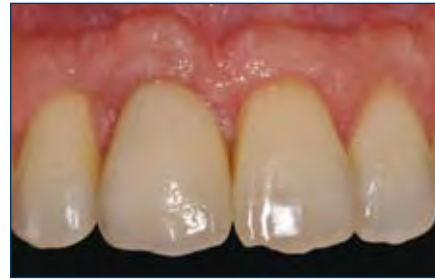**Figure 3m** A customized impression coping is designed to accurately capture the soft-tissue transition zone.



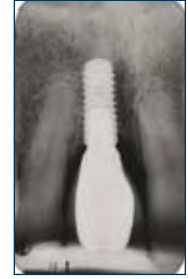**Figure 3n** A view of the CAD/CAM zirconia dioxide abutment prior to veneering with porcelain.



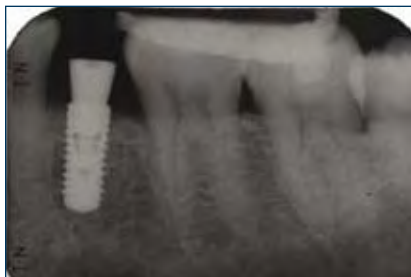**Figure 3o** A frontal view of the zirconia dioxide abutment post-veneering with porcelain.



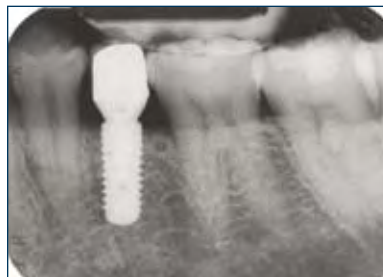**Figure 3p** A frontal view #8 at the one-year post-surgical follow-up.



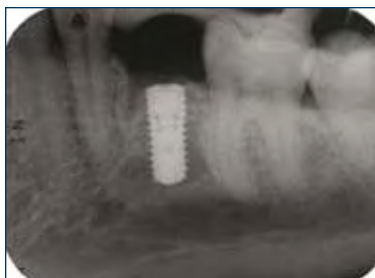**Figure 3q** A peri-apical radiograph at the one year post-surgical follow-up.



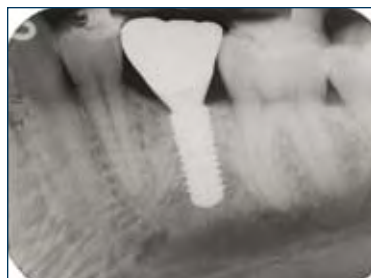
**Figure 4a** A post-surgical peri-apical radiograph of #20 – randomized for transmucosal healing.



**Figure 4b** A one-year post-surgical follow-up radiograph #20.



**Figure 5a** A post-surgical peri-apical radiograph #20 – randomized for submucosal healing.



**Figure 5b** A one-year post-surgical follow-up radiograph #20.

## References

1. Hermann JS, Buser D, Schenk RK, Schoolfield JD, Cochran DL. **Biologic width around one- and two-piece titanium implants.** *Clin Oral Implants Res* 2001;12:559-571.
2. Hermann JS, Schoolfield JD, Schenk RK, Buser D, Cochran DL. **Influence of the size of the microgap on crestal bone changes around titanium implants. A histometric evaluation of unloaded non-submerged implants in the canine mandible.** *J Periodontol.* 2001;72:1372-83.
3. Hermann JS, Schoolfield JD, Nummikoski PV, Buser D, Schenk RK, Cochran DL. **Crestal bone changes around titanium implants: a methodologic study comparing linear radiographic with histometric measurements.** *Int J Oral Maxillofac Implants.* 2001;16:475-85.
4. Hermann JS, Buser D, Schenk RK, Cochran DL. **Crestal bone changes around titanium implants. A histometric evaluation of unloaded non-submerged and submerged implants in the canine mandible.** *J Periodontol.* 2000;71:1412-24.
5. Cardaropoli G, Wennström JL, Lekholm U. **Peri-implant bone alterations in relation to inter-unit distances. A 3-year retrospective study.** *Clin Oral Implants Res.* 2003;14:430-6.
6. Alomrani AN, Hermann JS, Jones AA, Buser D, Schoolfield J, Cochran DL. **The effect of a machined collar on coronal hard tissue around titanium implants: a radiographic study in the canine mandible.** *Int J Oral Maxillofac Implants.* 2005;20:677-86.
7. Hänggi MP, Hänggi DC, Schoolfield JD, Meyer J, Cochran DL, Hermann JS. **Crestal bone changes around titanium implants. Part I: A retrospective radiographic evaluation in humans comparing two non-submerged implant designs with different machined collar lengths.** *J Periodontol.* 2005 May;76(5):791-802.
8. Hämmerle CH, Brägger U, Bürgin W, Lang NP. **The effect of subcrestal placement of the polished surface of ITI implants on marginal soft and hard tissues.** *Clin Oral Implants Res.* 1996 Jun;7(2):111-9.
9. Becker W, Becker BE, Ricci A, Bahat O, Rosenberg E, Rose LF, Handelsman M, Israelson H. **A prospective multicenter clinical trial comparing one- and two-stage titanium screw-shaped fixtures with one-stage plasma-sprayed solid-screw fixtures.** *Clin Implant Dent Relat Res.* 2000;2(3):159-65.
10. Lazzara RJ, Porter SS. **Platform switching: a new concept in implant dentistry for controlling postrestorative crestal bone levels.** *Int J Periodontics Restorative Dent.* 2006;26:9-17.
11. Chou CT, Morris HF, Ochi S, Walker L, DesRosiers D. **AICRG, Part II: Crestal bone loss associated with the Ankylos implant: loading to 36 months.** *J Oral Implantol.* 2004;30:134-43.
12. Hermann F, Lerner H, Palti A. **Factors influencing the preservation of the periimplant marginal bone.** *Implant Dent.* 2007;16:165-75.
13. Maeda Y, Miura J, Taki I, Sogo M. **Biomechanical analysis on platform switching: is there any biomechanical rationale?** *Clin Oral Implants Res.* 2007;18:581-4. Epub 2007 Jun 30.
14. Karlsson U, Gotfredsen K, Olsson C. **Single-tooth replacement by osseointegrated Astra Tech dental implants: a 2-year report.** *Int J Prosthodont.* 1997;10:318-24.
15. Kempainen P, Eskola S, Ylipaavalniemi P. **A comparative prospective clinical study of two single-tooth implants: a preliminary report of 102 implants.** *J Prosthet Dent.* 1997;77:382-7.
16. Norton MR. **Marginal bone levels at single tooth implants with a conical fixture design. The influence of surface macro- and microstructure.** *Clin Oral Implants Res.* 1998;9:91-9.
17. Puchades-Roman L, Palmer RM, Palmer PJ, Howe LC, Ide M, Wilson RF. **A clinical, radiographic, and microbiologic comparison of Astra Tech and Brånemark single tooth implants.** *Clin Implant Dent Relat Res.* 2000;2:78-84.
18. Palmer RM, Palmer PJ, Smith BJ. **A 5-year prospective study of Astra single tooth implants.** *Clin Oral Implants Res.* 2000;11:179-82.
19. Cooper L, Felton DA, Kugelberg CF, Ellner S, Chaffee N, Molina AL, Moriarty JD, Paquette D, Palmqvist U. **A multicenter 12-month evaluation of single-tooth implants restored 3 weeks after 1-stage surgery.** *Int J Oral Maxillofac Implants.* 2001;16:182-92.
20. Norton MR. **Biologic and mechanical stability of single-tooth implants: 4- to 7-year follow-up.** *Clin Implant Dent Relat Res.* 2001;3:214-20.
21. Gotfredsen K. **A 5-year prospective study of single-tooth replacements supported by the Astra Tech implant: a pilot study.** *Clin Implant Dent Relat Res.* 2004;6:1-8.
22. Wennström JL, Ekstubby A, Grvðndahl K, Karlsson S, Lindhe J. **Implant-supported single-tooth restorations: a 5-year prospective study.** *J Clin Periodontol.* 2005;32:567-74.



**Carlo Ercoli, DDS** graduated from the "Enrico Berlinguer" Dental Technology Institute in Rome in 1987 and obtained his dental degree from the University of Siena, Italy in 1993. He specialized in Prosthodontics in 1996 at the Eastman Dental Center in Rochester, New York, where he also completed a one-year training in Temporomandibular Joint Disorders in 1997. He is currently Director of the Prosthodontic Postgraduate Training Program at the University of Rochester, Eastman Dental Center. Dr. Ercoli is a diplomate of the American Board of Prosthodontics and holds memberships in several dental organizations including the American and International Association of Dental Research, the American College of Prosthodontists, Academy of Osseointegration, American Academy of Fixed Prosthodontics and American Prosthodontic Society. He has authored several publications and his research interests are focused on the biomechanics of dental implants, cutting protocols for bone and tooth preparation, and on clinical and laboratory testing of dental materials and techniques. He maintains an intramural practice limited to Prosthodontics. Dr. Ercoli has lectured nationally and internationally on several topics related to clinical prosthodontics and implant dentistry.

## Restoration of Immediately Placed Implants in 3 Appointments From Surgical Placement to Definitive Prosthesis

### Introduction

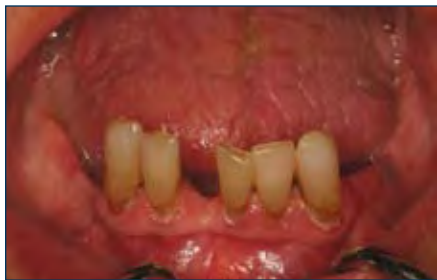A comprehensive approach is described which enables the clinician to place dental implants and fabricate a provisional prosthesis and a definitive metal-resin or metal-ceramic fixed complete denture in 3 appointments. This technique allows the practitioner to immediately load the implants with a provisional fixed complete denture at the time of implant placement, to record the relative positions of the implants and soft tissues, the occlusal vertical dimension, maxillomandibular relationship, and tooth position at the second appointment by using the information provided by the provisional

fixed denture; and to insert the definitive prosthesis at the third appointment. Chair time is reduced for both the patient and the clinician, and could ultimately decrease the cost of implant treatment and potentially increase treatment acceptance.

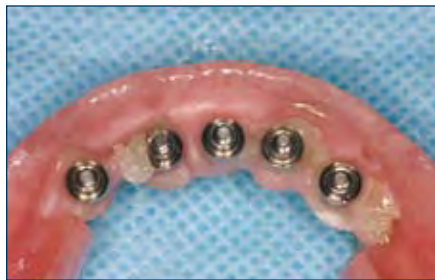### First Restorative Appointment

#### Technique:

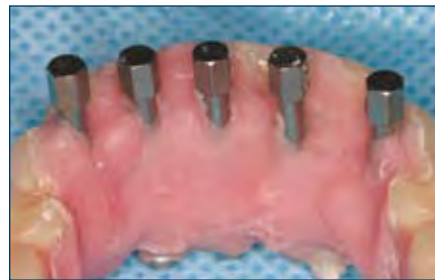1. Immediate complete denture(s) is/are fabricated for the patient utilizing light polymerizing resin Triad VLC, Denstply, York, PA.
2. Custom tray(s) is/are fabricated to fit over the denture(s) utilizing light polymerizing resin Triad VLC, Denstply, York, PA.
3. After the remaining teeth (Figure 1) are removed and implants are placed, (Straumann USA, Andover, MA) the implant carriers are removed. Screw retained posts (interim post, Straumann USA, Andover, MA) are hand tightened on each implant, to be utilized for interim fixed partial denture restoration.
4. A lingual flange of the previously fabricated immediate denture is



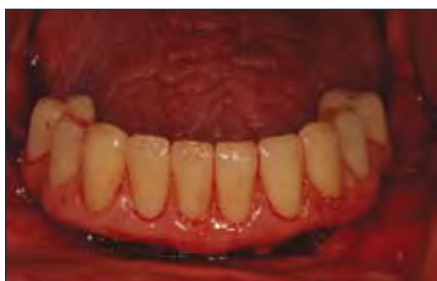**Figure 1** A preoperative buccal view of residual mandibular teeth.



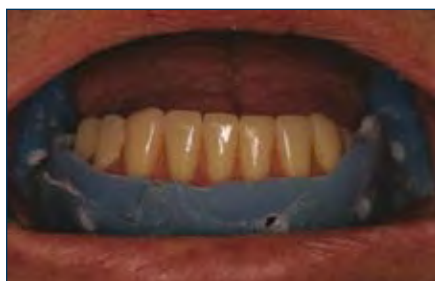**Figure 2a** A view of the intaglio surface of PRFCD connected to interim posts.



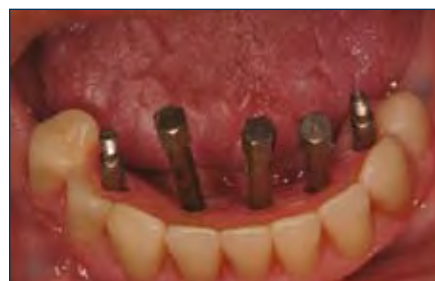**Figure 2b** A lingual view of PRFCD with impression cap handles in place to maintain access to the interim post screws. Auto-polymerizing acrylic resin has been added to recreate the lingual contour of the prosthesis.



**Figure 3a** A facial view of the completed PRFCD before final suturing. Note the prosthesis has been shortened to the second premolar tooth to limit posterior cantilever extension.



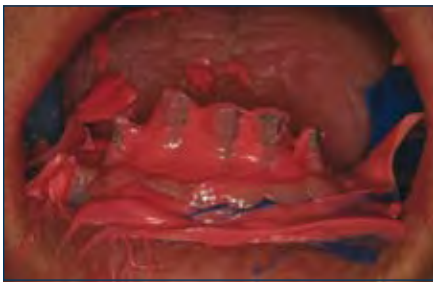**Figure 3b** A facial view of the impression tray placed intraorally. Note the tray (blue auto polymerizing resin) is completely open in the occlusal area of the prosthesis.



**Figure 4** A view of the PRFCD in place with impression cap handles and guide posts (latter in the most distal implants) to prevent the impression material from occluding the screw access openings.

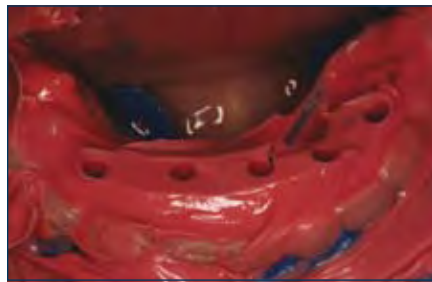removed to allow seating of the denture in the edentulous posterior areas without interference with the titanium interim posts. The denture is held in place utilizing finger pressure applied bilaterally to the posterior buccal flange areas. This pressure also serves to guide the patient to centric relation position, ensuring that occlusal contacts with the opposing arch are present.

- Light polymerizing acrylic resin (Unifast LC; GC America Inc, Alisip, IL) is employed to attach the entry portion of the denture to the interim titanium post. This is accomplished with the help of auxiliary personnel, while the correct position of the denture is maintained. A handle of impression cap (impression cap with built in handle, #048.090, Straumann, USA, Andover, MA) is placed in the screw access opening of each of the interim posts, to avoid acrylic getting into the screw access openings.
- Once all of the posts are connected to the denture, the impression cap handles are removed from the interim posts and the prosthesis is unscrewed from the implants (Figure 2a).



**Figure 5a** The impression phase: The impression cap handles or posts must be tall enough to protrude above the impression material.

- The handles of the impression caps are replaced in each access opening of the interim post and auto polymerizing pink acrylic resin (Jet Acrylic; Long Dental Mfg, Inc, Wheeling, IL) is applied to secure the post to the denture, and to recreate the lingual contours of the PRFCD (Figure 2b). If the implants have been placed within the mental foramina, or with a limited anterior posterior spread, the posterior extension of the denture distal to the second pre-molar are removed to limit posterior cantilever and moment forces. Additional resin is applied to make a PRFCD. When the implants are placed with a greater anterior posterior spread, the first or second molars are maintained in the PRFCD. In such patients, an impression is not taken at the second appointment and Steps Ten and Eleven are omitted. Care must be taken to ensure that sufficient embrasure space is available for the healing soft tissues and oral hygiene procedures.
- The PRFCD screws are torqued into the implants, fit is evaluated, and necessary adjustments to the occlusion are made to provide

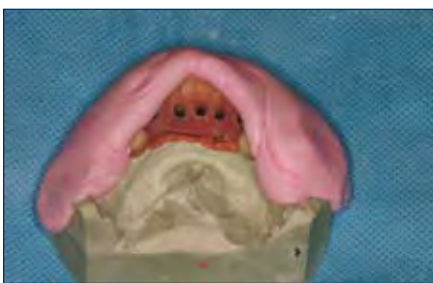

**Figure 5b** The cap handles and posts have been removed and the impression material around the screw access openings has been cut to allow insertion of a screw driver and unscrewing of the prosthesis.

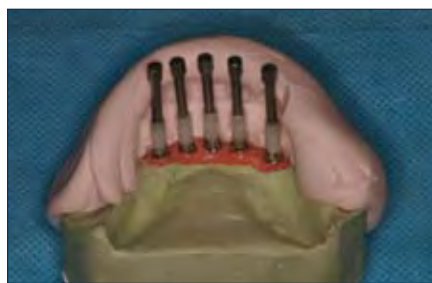bilateral contacts in centric occlusion. The screw access openings of the posts are obturated with cotton pellets and composite resin (Esghet Xflow; Dentsply, Caulk, Milford, DE) (Figure 3a).

### Second Restorative Appointment

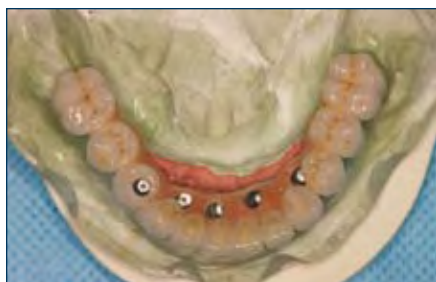- A maxillary mandibular relationship record is obtained with PRFCD in place, using vinyl polysiloxane (VBS) material. (Memoreg 2; Heraus Kulzer, Hanau, Germany).
- If the PRFCD has been fabricated with a second pre-molar occlusion, the custom tray made in Step One is modified by removing the occlusal area of the tray corresponding these PRFCD teeth positions. the tray is evaluated intraorally to ensure that it may be placed without interference with the provisional prosthesis (Figure 3b). The composite and cotton pellets are removed from the screw access openings.
- The handle guide post of an impression cap is secured in the access opening of each interim post, to prevent impression material from flowing inside the interim post (Figure 4). An impression is made with polyether material (Permadyne Penta H; 3M ESPE, Seefeld, Germany). Care must be taken to ensure that the light body material (Permadyne Garant; 3M ESPE, Seefeld, Germany) is injected below the provisional prosthesis, and that the handles of the impression caps protrude through the tray opening (Figure 5a). Once the material has polymerized, the impression cap handles are removed from the square access openings with cotton pliers, and the excess impression material is trimmed away with a surgical blade (Figure 5b).
- The PRFCD is unscrewed using a long screwdriver (SCS Screwdriver, 046-402; Straumann USA, Andover, MA) and the prosthesis is removed from the mouth.
- Implant analogs (synOcta® Analog, Straumann USA, Andover, MA) are hand torqued to the interim posts embedded in the PRFCD, and a cast is poured with type 4 dental stone (Resin Rock; Whip Mix CO, Louisville, KY), with slurry water added to accelerate stone setting.



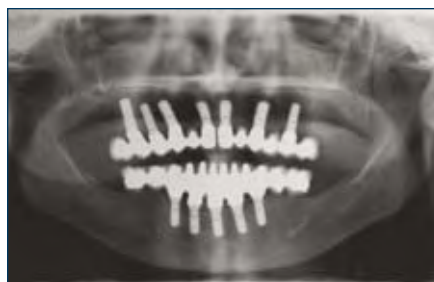**Figure 6a** A buccal index of the PRFCD on definitive cast records 3-dimensional tooth positions and the outline of the acrylic resin replacing the missing soft tissues.



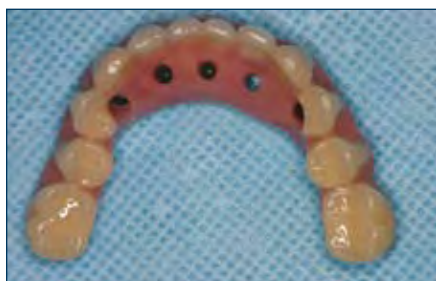**Figure 6b** A view of the definitive cast with cast-to prosthetic cylinders and the buccal index in place. Impression cap handles were placed in the cylinders to avoid inadvertently placing wax or acrylic resin in the screw access openings during laboratory procedures.



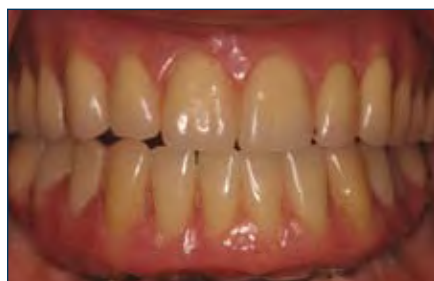**Figure 7a** An occlusal view of the MCFCD on the definitive cast, fabricated by the proposed technique.



**Figure 7b** A panoramic radiograph of the mandibular MCFCD shown in Figure 7a. Note the radiographic evidence of prosthesis fit. The occlusal vertical dimension of the metal connectors decreases the likelihood of porcelain and/or metal fracture. The maxillary prosthesis is a previously fabricated metal-ceramic fixed partial denture.



**Figure 8a** An occlusal view of the MRFCD fabricated using the proposed technique.



**Figure 8b** A buccal view of maxillary complete denture and mandibular MRFCD.

14. If an impression was made, the impression tray is sectioned and the cast is recovered. Four notches are made on the buccal surface of the cast for indexing purposes and the BPS buccal index is fabricated (Lab putty; Colten/Whaledent, Mahwah, NJ) extending to the occlusal surfaces of the dentured teeth. (Figure 6a).
15. The BPS index is removed and stored for future use during laboratory procedures. The cast is mounted against the previously made maxillary cast, using records obtained in Step Thirteen, on a semi-adjustable articulator (Mounting Stone; Whip Mix CO, Louisville, KY). Adhesive tape is placed on the incisal pin to record the vertical dimension of the provisional prosthesis. Once the stone has set, the PRFCD is removed from the cast and screwed back into position intraorally. The screw access holes are obturated as previously described, and the patient is dismissed.
16. The laboratory is provided with the mounting casts and the buccal matrix to fabricate the definitive prosthesis. The laboratory technician is asked to position the buccal matrix on the cast to guide framework application, porcelain application in the case of a metal ceramic prosthesis, or an acrylic resin tooth arrangement for a metal acrylic resin prosthesis (Figure 6b). The laboratory is instructed to complete fabrication of the prosthesis (Figures 7a, 8a).

### Third Restorative Appointment

17. The fit of the prosthesis is verified at the third appointment (Figures 7b, 8b). If necessary, minor occlusal adjustments are performed. At a two week follow up appointment, the patient is placed on an appropriate recall schedule.

### Summary

A comprehensive approach is described for fabrication of a provisional restoration and a definitive implant-supported metal and resin or metal-ceramic fixed complete prosthesis in the anterior mandible, in 3 appointments. While the procedures involved in the insertion of a fixed prosthesis at the time of implant placement have been described, the primary advantage of this technique is that all the information needed for definitive prosthesis fabrication is incorporated into the provisional immediate fixed prosthesis and transmitted to the laboratory in a single appointment. This technique, while allowing the fabrication of an esthetic and functional prosthesis, reduces chair time for both the patient and the clinician and could ultimately reduce the cost of implant treatment, potentially increasing treatment acceptance.





**Brody J. Hildebrand, DDS, MS** received a BA in Biology while at Baylor University and a DDS from Baylor College of Dentistry in Dallas. Dr. Hildebrand followed his DDS by completing a dual certificate program receiving specialty certification in both Orthodontics and Prosthodontics at Baylor as well as a MS in Oral Biology. He is a board certified orthodontist (AAO/ABO) and board eligible prosthodontist (ACP/ABP). Dr. Hildebrand practices both specialties in the Dallas area and continues as an Assistant Clinical Professor in the Graduate Prosthodontics Residency program at Baylor College of Dentistry. He teaches several courses to graduate and undergraduate students covering implants and technology and continues exploring research opportunities associated with implants and orthodontics. Dr. Hildebrand is active in several local, regional, national and international professional organizations including the ACP, AAO, AO, AGD, NFED and ITI. He serves on the Scientific Advisory Board of the National Foundation of Ectodermal Dysplasias (NFED) and is a Fellow of the International Team for Implantology (ITI).

## From Casting to CAD/CAM: Technology Affecting Clinicians Today

Technology has taken hold of dentistry once again and transformed the procedures, the materials, and the processes by which the dental team fabricates the restorations. Decisions on delivery of laboratory materials are complex and demanding on the dental professionals of today. There are a myriad of choices. Potential advantages and disadvantages must be weighed without attention being paid to marketing techniques. The fear of any practitioner would be to "dive in head first" and later face unknown factors that might plague the restorative units down the road- be it material degradation, luting agents, handling issues, or other unknown factors. Such an occurrence would prove costly and be detrimental to private practice.

When selecting implant restorative components, choices revolve around additional factors. Accuracy, strength, and aesthetics associated with the restorative choices all warrant attention. This article will briefly review these three areas, which play a critical role when the private practitioner is looking to utilize CAD/CAM technology as a restorative option.

Accuracy of fit/milling capabilities: Marginal accuracy of dental restorations plays an important role in the construction of any fixed prosthesis. Although there is no consensus as to what constitutes an acceptable marginal fit<sup>1</sup>, numerous clinicians speak of "clinically acceptable" gaps. Generally accepted ranges run from 50  $\mu$ m up to

119  $\mu$ m.<sup>2-4</sup> The goal of a 25-50  $\mu$ m gap, while admirable, is seldom obtained by conventional methods.<sup>5</sup> When considering CAD/CAM coping creation, there is a significant relationship between a restoration's marginal discrepancy and periodontal health. In addition, teeth with restorations of inadequate marginal integrity are prone to failure, primarily due to recurrent caries.<sup>6,7</sup> Accuracy of the milling capabilities of CAD/CAM machines has dramatically improved over the last decade. In the late 1980's and beginning of the 1990's, all-ceramic system, such as IPS Empress (Ivoclar Vivadent), InCeram (Vita), and Procera (Nobel Biocare) gained popularity and were integrated into prosthodontics as an acceptable treatment modality option for demanding esthetic cases.

Improvements in strength, color stability, and gingival response were some of the advantages of this new restorative modality.<sup>8,9</sup> However, the fit, marginal integrity and long term strength of the restorations did not instill great enthusiasm.

Although the marginal gap range for Procera AllCeram crowns was within clinically acceptable ranges, it was found to be significantly greater than the mean marginal gap for metal-ceramic crowns.<sup>10,11</sup> The advent of laser-driven scanners such as the es1 and larger multi-axis milling machines, as well as the advancements in strength through the use of zirconium dioxide materials, have

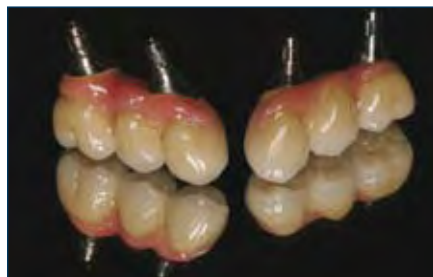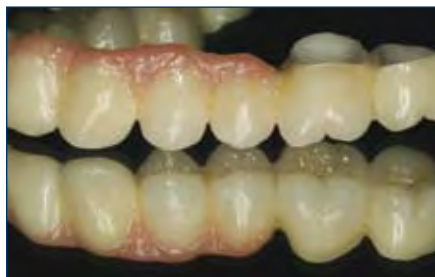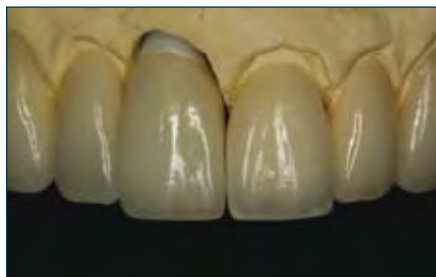resulted in increased levels of acceptance of CAD/CAM restorations. Recent studies have validated the accuracy of CAD/CAM restorations. The precision of fit for frameworks milled by CAD/CAM machines in milling centers has been superior to that of frameworks fabricated by in-office milling machines and optical scanners.<sup>12</sup>

### Strength of Materials

In the past several years, partially stabilized zirconia has been introduced as a restorative material. The primary advantage of the newer zirconium materials is their strength compared to densely sintered and compacted particle distribution.

The dense particle position not only adds strength, but also acts to retard crack propagation. When a crack begins to move through the material a phase transformation occurs at the leading edges of the crack and subsequent expansion of the individual particles occurs at the stress points.

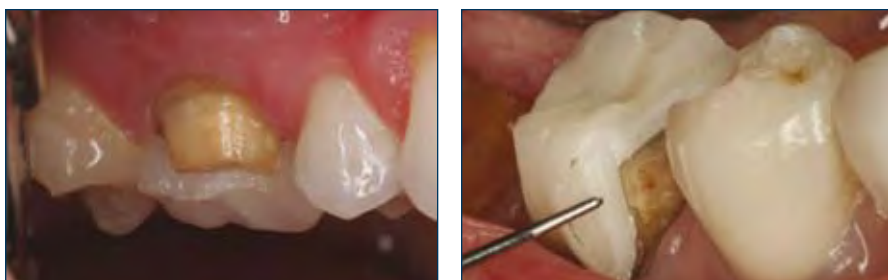While this characteristic is useful for stopping crack propagation and thus subsequent restoration failure, it is important to note that phase transformation can be created iatrogenically. Extreme care must be taken by all parties involved in the fabrication of zirconium restorations and abutments. Laboratory support staff must be trained to use neither the convenience



**Figures 1a, 1b, 1c** CAD/CAM is utilized to create beautiful and strong crowns for restorations for single and multiple units on implants or natural teeth.



Figure 2 CAD/CAM milling samples from various developmental stages over the years.



Figures 3a, 3b Fracture of restorations without adequate support structure to withstand strong occlusal forces.



Figures 4a, 4b, 4c Straumann® CAD/CAM scanning and milling.

of coarse grit burs nor the customary slow speed drill devices. Restorative clinicians must be extremely cautious when making internal adjustment to copings or abutments to achieve intra-oral seating. Anything less than a fine grit diamond used at a moderate to high speed with copious irrigation and light pressure will have the propensity to create microscopic cracks in the copings. These cracks are terminated as the zirconium particles go through their phase transformation. However, in doing so they create expansive inclusions into the abutment or crown coping which may not be evident initially. The aging process of water absorption and resultant progressive nucleation creates continued phase transformation, and thus continued expansion leading to eventual failure at the abutment or coping interface.

Traditional strength tests put the early aluminum oxide materials at around 600

Mpa, while the newer zirconium dioxide materials are nearing or exceeding 1000 Mpa. The strength of the copings and abutments is high enough to withstand the forces of most clinical situations in the oral cavity.

While creation of a secondary coping over an abutment relies on the accuracy of the coping for adequate fit, the strength of the abutment becomes more crucial to the long term success of the entire restorative complex. Another option is to create the crown and abutment in one unit. The provisional and final restorations do not have to follow one another in design.

Fortunately, the advances in zirconium have produced strengths that well exceed those encountered with normal mastication. Recent studies have shown the failure loads of fixed partial denture restorations made of zirconium dioxide

exceed 2,000 N. In the same study, failure loads for other zirconium and aluminum coping materials were at best half as high.<sup>13</sup> Performance of this magnitude addresses the strength argument often leveled against zirconium ceramic restorations.

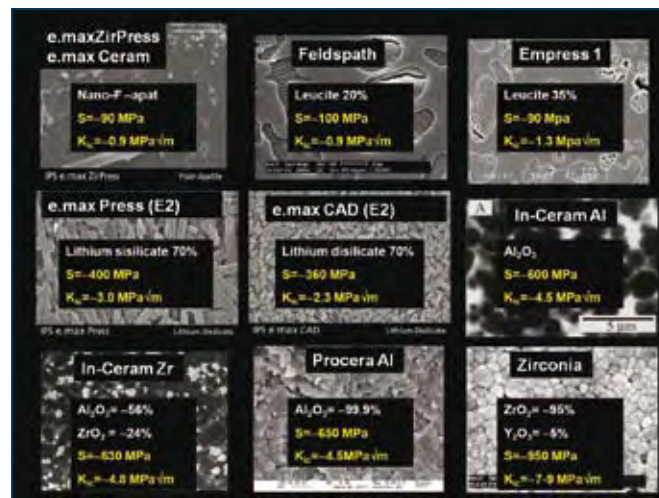
CAD/CAM technology is not limited to only the fabrication of ceramic copings and abutments. It also allows for the creation of metal abutments and copings. Investigation of the marginal fit and strength of zirconium dioxide ceramic copings manufactured using CAD/CAM based-techniques demonstrated that both marginal integrity and strength were superior to previous CAD/CAM materials.<sup>14,15</sup> While not appropriate for all patients and esthetic conditions, the manpower and laboratory time involved with CAD/CAM creation of metal/zirconium copings or abutments is substantially reduced.

Primary laboratory advantages are of CAD/CAM include:

1. The ability to quickly create digital renditions of the desired anatomical shape for any specific restoration.
2. The ability to work on multiple units.
3. The ability to reference digital analysis software of the line of draw of a restoration.
4. The ability to quickly and efficiently remake copings or abutments that do not meet accuracy or strength standards without extensive preparatory work.
5. The ability to avoid the substantial energy requirements, natural resources, and variable costs associated with creation of a coping or an abutment made of gold through the lost wax technique.
6. The cultural and technological appeal to the workforce of today.

### Esthetics

It is difficult to deny the inherent increased potential for aesthetics which all ceramic restorations afford. When trying to recreate natural tooth optics, most laboratory technicians will agree that the elimination of the metal substructure is a plus. However, concrete evidence about visual differences within the tissues is often debatable. One of the crucial areas to consider is the tissues



Figures 5a, 5b Scanning Electron Microscopy highlights the microstructure that gives strength to various ceramic restorative materials.

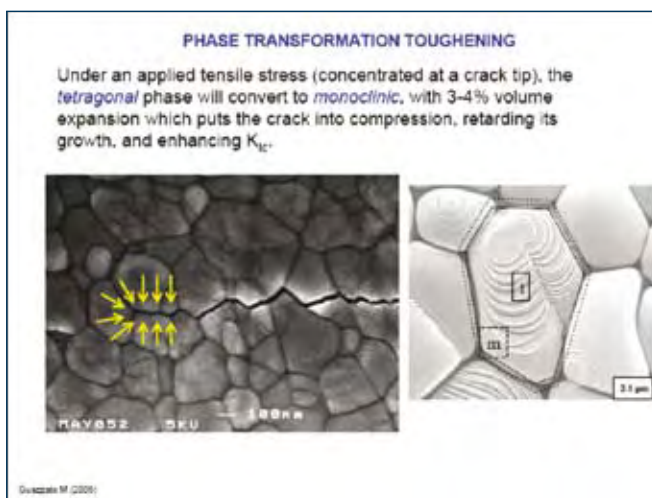


Figure 6a Crack propagation is halted by phase transformation in zirconium materials.

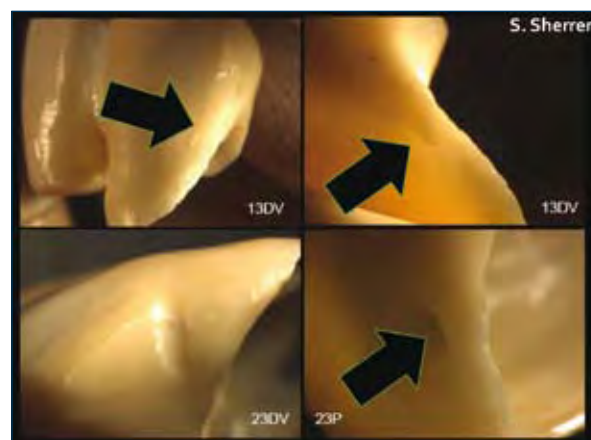


Figure 6b Cracks can be created by post sintering adjustments with course diamonds and a lack of cooling during adjustment, leaving a potential weakness in the material that could affect the longevity of the restoration.

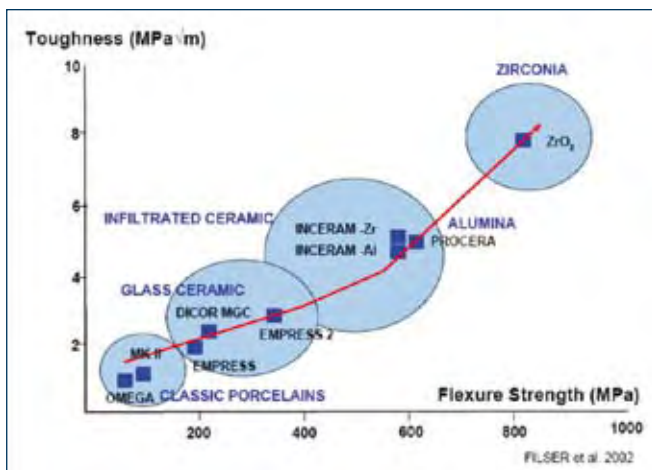


Figure 7a A graph demonstrating the strength of ceramic restorative materials.

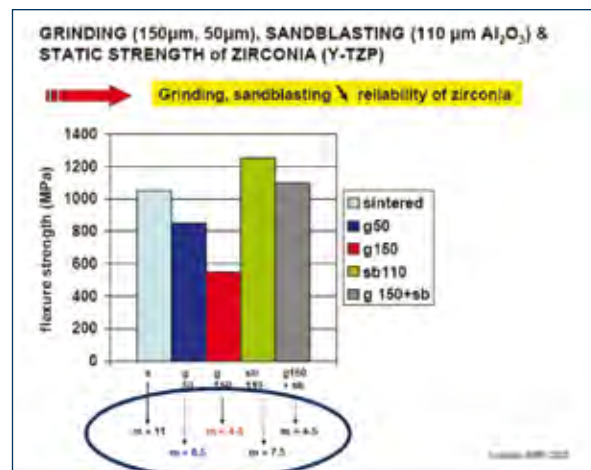


Figure 7b A graph of the effect of grinding and/or sandblasting on the strength of zirconia.

surrounding the tooth or implant. Thicker tissues have a greater propensity to mask the discoloration that may come from a dark root, a titanium abutment, or a darkening around the cervical portion of a tooth due to metal trans-illumination through the root from the coping.

Evidence now suggests that zirconium materials, whether copings or abutments, have the least propensity to induce tissue coloration changes.<sup>16,17</sup>

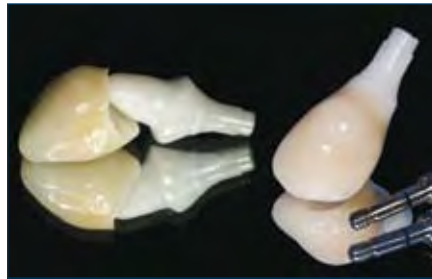
Due adequate strength, ease of fabrication, potential minimal cost differences, and aesthetics that are more easily obtained, even the most skeptical clinician begins to reevaluate long held beliefs that traditional metal restorative materials are the optimal means by which to provide longevity.

Technological advances in dentistry continue at an ever increasing rate. It is critically important to decipher which advances are worth utilizing. Zirconium dioxide materials are worth using in terms of clinical fit, strength, and aesthetics.

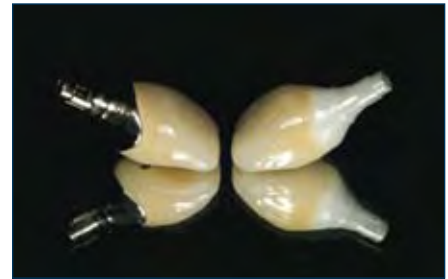Naturally, continued research is prudent. Future advancements will put more distance between traditional techniques and materials and what technology can offer to restorative and implant dentistry. The addition in the Straumann CAD/CAM system affords expanded opportunities for the clinician utilizing CAD/CAM technology.



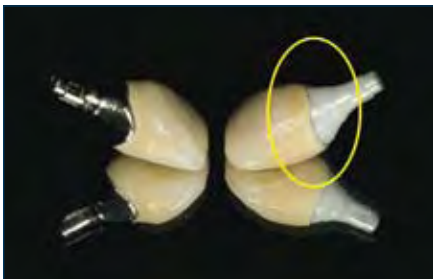
**Figure 8a** A view of a final restoration with contours to mimic provisional restoration.



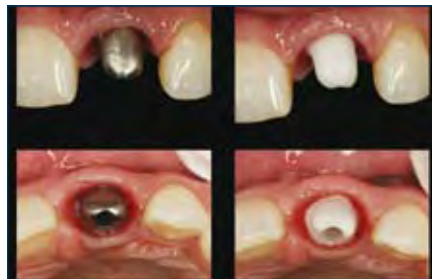**Figure 8b** Options for a cement retained and screw retained restoration with zirconium substructure are pictured.



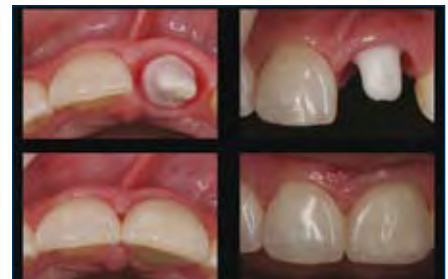**Figure 9a** Options for milled abutment with a titanium abutment and porcelain fused to metal crown opposing a zirconium abutment and a porcelain fused to zirconium crown are pictured.



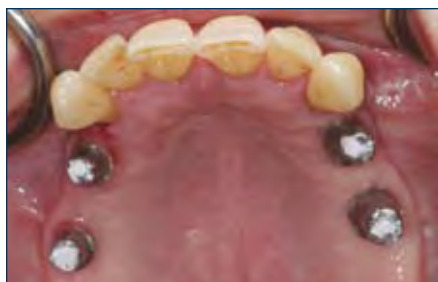**Figure 9b** Interchanging the crowns on the milled abutments reveals how the metal substructure of the porcelain fused to metal crown creates a transference of grayness onto the abutment.



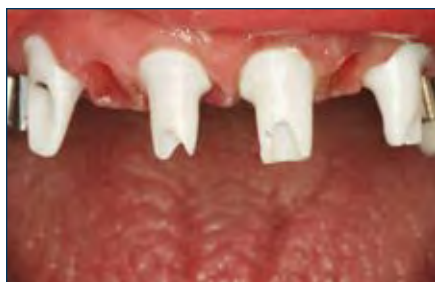**Figure 10a** Views of a titanium milled abutment and a zirconium milled abutment on the implant. With adequate gingival thickness and support both abutments would work well esthetically.



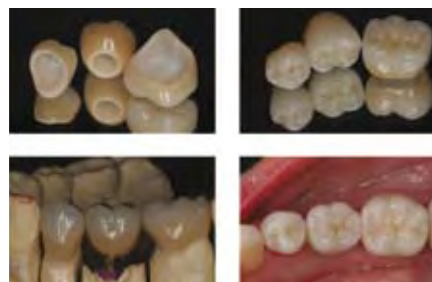**Figure 10b** A zirconium abutment is chosen, and the crown is in place.



**Figure 11a** Titanium milled abutments in the patient's right posterior sextant and anatomic titanium abutments in the patient's left posterior sextant both provide adequate support and a cost effective abutment solution.



**Figure 11b** Zirconium abutments provide superior esthetics for anterior restorations, on tissue or bone level implant platforms. This illustration is on tissue level implants.



**Figure 11c** Restorative units can all be created out of the same material, offering consistency in esthetics independent of the type of tooth being restored.



**Figure 12** Straumann® CAD/CAM and emax provide accuracy, strength, and expanded options for restoration of natural teeth or dental implants.

## References

- Hunter AJ and AR Hunter. **Gingival margins for crowns: a review and discussion. Part II: Discrepancies and configurations.** *J Prosthet Dent* 1990. 64:636-42.
- Bronson MR, TJ Lindquist, and DV Dawson. **Clinical acceptability of crown margins versus marginal gaps as determined by pre-doctoral students and prosthodontists.** *J Prosthodont* 2005. 14:226-32.
- Christensen GJ. **Marginal fit of gold inlay castings.** *J Prosthet Dent*, 1966. 16:297-305.
- Ostlund LE. **Cavity design and mathematics: their effect on gaps at the margins of cast restorations.** *Oper Dent* 1985. 10:122-37.
- Fransson B, G Oilo, and R Gjeitanger. **The fit of metal-ceramic crowns, a clinical study.** *Dent Mater* 1985. 1:197-9.
- Felton DA et al. **Effect of in vivo crown margin discrepancies on periodontal health.** *J Prosthet Dent*. 1991. 65:357-64.
- Walton JN, FM Gardner, and JR Agar. **A survey of crown and fixed partial denture failures: length of service and reasons for replacement.** *J Prosthet Dent*. 1986. 56:416-21.
- May KB et al. **Precision of fit: the Procera AllCeram crown.** *J Prosthet Dent*. 1998. 80:394-404.
- Quintas AF, F Oliveira, and MA Bottino. **Vertical marginal discrepancy of ceramic copings with different ceramic materials, finish lines, and luting agents: an in vitro evaluation.** *J Prosthet Dent*. 2004. 92: 250-7.
- McLean JW and JA von Fraunhofer. **The estimation of cement film thickness by an in vivo technique.** *Br Dent J*. 1971. 131:107-11.
- Albert FE and OM El-Mowafy. **Marginal adaptation and microleakage of Procera AllCeram crowns with four cements.** *Int J Prosthodont*. 2004. 17:529-35.
- Beuer R, Aggstaller H, Edelhoff D, Gernet W, Sorensen J. **Marginal and internal fits of fixed dental prostheses zirconia retainers.** *Dent Mater* 2009. 25:94-102.
- Tinscher J, Natt G, Mautsch W, Augthun M, Spiekermann H. **Fracture resistance of lithium disilicate-, alumina-, and zirconia-based three-unit fixed parital dentures: a laboratory study.** *Int J Prosthodont*. 2001. 14:231-8.
- Coli P and S Karlsson. **Fit of a new pressure-sintered zirconium dioxide coping.** *Int J Prosthodont*, 2004. 17: 59-64.
- Witkowski S, F Komine, and T Gerds, **Marginal accuracy of titanium copings fabricated by casting and CAD/CAM techniques.** *J Prosthet Dent*. 2006. 96: 47-52.
- Jung RE, Sailer I, Hammerle CH, Attin T, Schmidlin P. **In vitro color changes of soft tissues caused by restorative materials.** *Int J Periodontics Restorative Dent*. 2007. 27:251-7.
- Jung RE, Holderegger C, Sailer I, Khraisat A, Suter A, Hammerle CH. **The effect of all-ceramic and porcelain-fused -to-metal restorations on marginal peri-implant soft tissue color: a randomized controlled clinical trial.** *Int J Periodontics Restorative Dent*, 2008. 28:357-65.





**Robert A. Levine, DDS** maintains a full time practice in Northeast Philadelphia focusing on Surgical Implant Placement, Cosmetic Oral Plastic Surgery Procedures, Regenerative Therapy, Adult Orthodontics and Oral Medicine. He is Chairman Emeritus of Periodontics at Albert Einstein Medical Center (1984-2003) and presently is Clinical Associate Professor of Periodontics in the Post-Graduate Department of Periodontics, Periodontal Prosthesis and Implantology at the University of Pennsylvania School of Dental Medicine. Dr. Levine is a Fellow of the International Team for Implantology (ITI) and a Fellow of the College of Physicians in Philadelphia, PA. He is a visiting lecturer at Temple University, New York University, Nova Southeastern University and University of North Carolina Schools of Dentistry. Dr. Levine is a Diplomate of the American Board of Periodontology and serves on the Editorial Boards of five international scientific journals.

## Optimizing SLActive® Surface Technology to Reduce Treatment Time, Maximize Predictability and Increase Patient Satisfaction

### Background

Research began in the late 1980's to develop an implant surface which could replace the titanium-plasma-sprayed surface (TPS) with a non-coated titanium surface, through further development of surface topography. In a series of animal studies, a sand-blasted and acid-etched surface (SLA®) demonstrated histomorphometrically significantly better bone apposition and higher removal torque values than TPS and traditional polished titanium surfaces.<sup>1-4</sup>

Clinical studies documenting restoration of SLA implants after a healing period of only 6 weeks showed survival rates equal to or better than those of traditionally restored TPS implants.<sup>5-10</sup> Early loading became the accepted loading protocol for restoring dental implants with SLA surfaces.<sup>11</sup>

The influence of physical properties on osseointegration, such as the SLA surface topography and roughness, has translated into shortening of treatment times for patients. The modifications of the SLA implant surface chemistry may lead to alterations in the

structure of adsorbed proteins, and have cascading effects that may ultimately be seen clinically.<sup>12,13</sup> The SLActive surface (Straumann AG, Basel, Switz), uses the topography of the SLA surface and is chemically modified and characterized by a hydroxylated/hydrated TiO<sub>2</sub> film, carried out under N<sub>2</sub> conditions. The continuous submersion of the implants in an isotonic solution appears to protect the titanium surfaces from contamination with organic components and carbonates which are naturally occurring in the atmosphere, thus preserving a clean and reactive surface.<sup>14</sup> The SLActive surface has a high surface free energy and is strongly hydrophilic, with a water contact angle of 0 degrees as compared with 139.9 degrees for the SLA surface<sup>13,14</sup> (Figures 1-2). Such an interaction accelerates and enhances bone deposition and therefore osseointegration (Figure 3), allowing further reduction in healing time and providing greater stability early in healing, when the stability of the implant is generally decreased. In vivo studies evaluating bone-implant-contact (BIC) with the SLA surface and the chemically modified-SLA surface, showed 60% more bone at 2 weeks with the chemically modified surface, and a

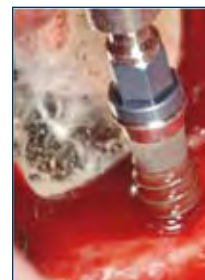significantly enhanced BIC during the first 4 weeks of healing, with earlier formation of more mature bone, as compared to the SLA surface.<sup>15,16</sup> Mean removal torque values were consistently higher in the first 8 weeks with the SLActive® surface.<sup>17</sup> Enhanced bone formation, significantly increased cellular activity and proliferation of vascular structures, and greater connective tissue attachment with well-organized collagen fibers and blood vessels have been documented with SLActive compared to SLA.<sup>18,19</sup> A "shifting of the dip" of implant stability from decreasing stability to increasing stability was demonstrated in a clinical human pilot study after 2 weeks for the chemically modified test surfaces, as compared to after 4 weeks for the standard SLA control implants (Figures 4,5).<sup>24</sup> A 12-month multicenter clinical study demonstrated that chemically modified SLActive surface implants are predictable with early and immediate loading protocols, even in poor-quality bone, yielding results comparable to those achieved with conventional loading.<sup>20</sup> The data from these recent SLActive studies suggest a direct patient benefit of reduction of the healing period following implant placement to 3-4 weeks.<sup>12</sup>



**Figure 1** A drop of sterile saline is placed on the hydrophobic SLA® surface. The bead of water sits atop the SLA® surface due to the water contact angle of 139.9 degrees.




**Figure 2** A bead of sterile saline is immediately absorbed into the chemically modified SLActive® surface. The SLActive® surface has a high surface free energy and is strongly hydrophilic, with a water contact angle of 0 degrees.



**Figure 3** A view of a SLActive® surface of a RN implant placed during mandibular implant immediate load surgery (area #26). Immediate blood absorption is noted, which defies gravity as it wicks in an upward direction, due to the hydrophilic nature of its surface. Such an interaction has been shown to accelerate and enhance bone deposition and osseointegration.

Chemically modified SLActive surface implants used in more clinically demanding situations such as immediate loading and type 4 maxillary bone, have shown improved patient outcomes and improved patient comfort during the healing phase, with survival rates comparable to conventional healing protocols.<sup>20-24</sup>

A prospective 5-year clinical study evaluated the survival rates and prosthetic complications of SLActive posterior (molars/pre-molars) single tooth implants restored between 3-4 weeks after placement with final restorations, and clinical and radiographic follow-up to 2.5 years. Such an approach reduces treatment time and helps maximize predictability and patient satisfaction.

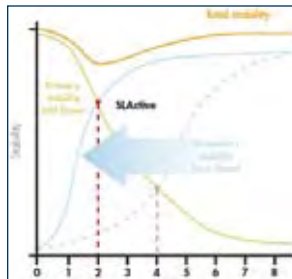


**Figure 4** Traditional dental implants experience a stability dip between weeks 2 and 4, when the mechanical primary stability has begun eroding and the biologic secondary stability is not far enough along. Traditional implants are at the greatest risk during this time period for early failure.

## Study Background

22 patients (8 females and 14 males) 39-78 years of age (average 53.9 years) were enrolled at the start of the study (July 2006) and received 25 implants. Patients needed to be healthy and at least 21 years of age, with sufficient ridge height/width to accept either a Wide-neck (WN) or Regular Neck (RN) Straumann dental implant.

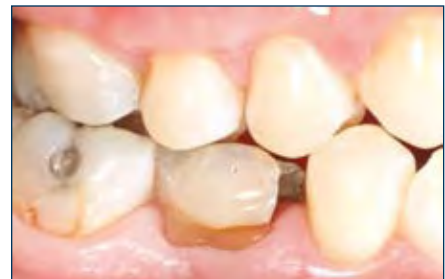A diagnostic wax-up was carried out, with fabrication of an anatomically correct surgical guide template to allow for proper 3-dimensional implant placement.<sup>25</sup> Initial non-surgical therapy or oral hygiene instructions were carried out as necessary.



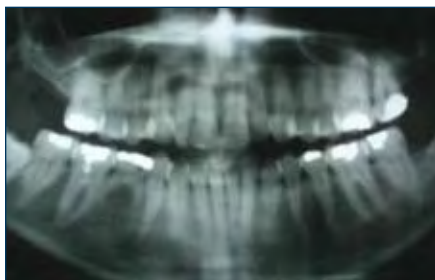
**Figure 5** "Shifting of the Dip" is noted due to the hydrophilic nature of the SLActive<sup>®</sup> surface. In vivo studies evaluating bone-implant-contacts (BIC), comparing the standard SLA<sup>®</sup> surface with a chemically modified-SLA<sup>®</sup> surface, showed 60% more bone at 2 weeks with the chemically modified surface and a significantly enhanced BIC during the first 4 weeks with earlier formation of more mature bone, as compared to the standard SLA<sup>®</sup> surface.

## Surgical Procedure

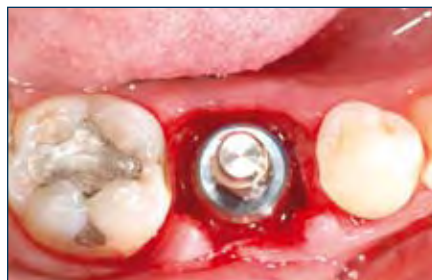Incisions were made in the edentulous areas to maximize keratinized gingiva facially, upon closure. Full-thickness flaps were raised. Straumann regular-neck (RN) or wide-neck (WN) SLActive surface implants were placed according to the manufacturer's recommended protocol.<sup>26</sup> The only exception was the substitution of the 3.5 mm trephine drill for the 3.5 mm twist drill. The implants were placed without pre-tapping, to optimize primary stability. An intra-surgical digital x-ray was taken to confirm appropriate depth and subsequent final implant length. All sites had at least 1 mm of bone buccal and lingual to the implant after placement. The implants were inserted by hand with a Straumann torque wrench device. If a 35 Ncm insertion torque was achieved, the patient was enrolled in the study.



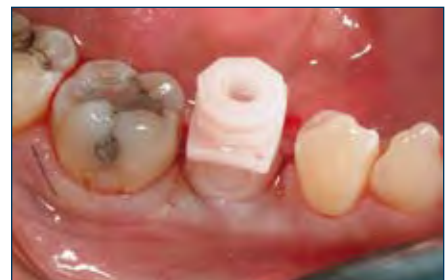**Figure 6** A pre-operative view. The primary first molar will be removed due to extensive caries, and an immediate implant will be placed.



**Figure 7** A pre-operative panorex radiograph of the lower right primary molar which will be removed and replaced with a dental implant.



**Figure 8** A wide neck (WN) implant is placed to a 35 Ncm hand delivered torque, with the aid of an anatomically correct surgical guide template.



**Figure 9** A closed tray synOcta<sup>®</sup> WN impression is taken the day of implant placement. Delivery of the final crown will take place in 3 weeks, pending a successful reverse torque test (RTT) at 35 Ncm.

Implants were placed to allow implant buccal shoulders to be in the correct prosthetic position, with allowing sufficient keratinized mucosa to cover the shoulder after flap suturing, enhancing the ability to develop an appropriate emergence profile in the final restoration. Occlusal reduction of the corresponding maxillary tooth was completed if supra-eruption was evident. An elastomeric impression was taken with synOcta impression parts within 24 hours of surgery (Figures 6-9). The dental laboratory was advised to fabricate ideal interproximal and subgingival crown contours for the final crown, to allow for ongoing soft tissue maturation. The flaps were contoured as needed around the healing abutment and sutured with 4-0 silk or 4-0 chromic gut. Post-operative instructions were reviewed, including avoiding chewing on the side of the surgery until the final crown was placed. A chlorhexidine gluconate mouthwash was used for 2 weeks bid, and an NSAID was employed for 3-5 days, due to its anti-inflammatory and analgesic properties. Periapical radiographs were obtained using a long-cone parallel technique prior to dismissing the patient, the day of final crown insertion (at 3-4 weeks) and at the final post-treatment appointment (up to 2.5 years).

### Post-operative Period

Each patient was followed with post-operative appointments at 2 weeks and 3-4 weeks when the healing cap was removed, a long-cone parallel periapical x-ray was taken, the soft tissues were assessed and bone healing was confirmed with a reverse torque test (RTT) using an implant carrier device at 35 Ncm. Final abutment fabrication and crown insertion were carried out (Figures 10, 11). Preventative periodontal maintenance schedules were determined for each patient on an individual basis.

Radiographic analysis of crestal bone changes (DIB) were made, comparing bone levels at final crown placement and the end of the study period (range 6 months - 2.5 years) (Figures 12-15). The gain or loss of bone was measured using the change in the DIB values (the distance between the implant shoulder and the most coronal visible bone-to-implant contact at the mesial and distal aspects of each implant) between periods.<sup>18,20</sup>

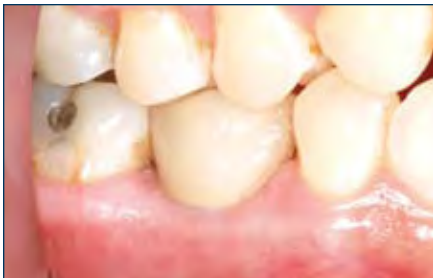Hard tissue changes ranged from a gain of 0.2 mm to a loss of less than 1 mm. Soft tissue changes were documented with clinical photography at each of the follow-up visits.

Peri implant examinations were completed, noting probing depths and bleeding upon probing sites.

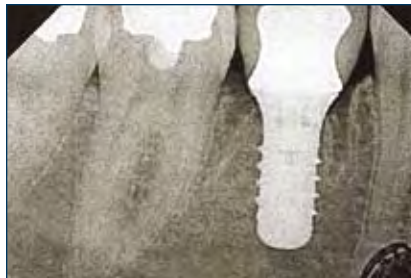Based on clinical and radiographic findings, each implant was classified as a success or a failure using the criteria of Buser et al.<sup>27</sup>

### Results

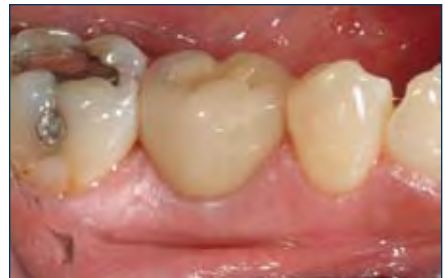Fourteen wide-neck and 11 regular-neck SLActive implants were placed in maxillary (n=9: 2 molars; 7 pre-molars) and mandibular (n=16: 12 molars; 4 pre-molars) posterior areas; There were no complications during the healing phase. At 3-4 weeks, when the confirmation of bone healing was determined by a reverse torque of the abutment carrier, 4 "spinners" with discomfort were noted. These implants were allowed to heal an additional 4-6 weeks, and were re-torqued successfully at that time. Soft tissue maturation was not complete at 3-4 weeks. At 6 months to 1 year post implant insertion soft tissue filling of the interproximal areas was routinely seen. Radiographs were evaluated in the most magnified mode (17 inch screen) of the digital image with Dexis software (Dexis LLC, 901 West Oakton St., Des Plaines, IL 60018). Bleeding upon probing was associated with 2 implants.



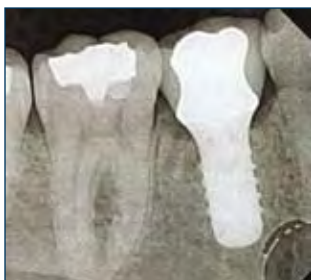**Figure 10** A view of the final crown delivery in full occlusion at 3 weeks. Note the position of the interproximal soft tissues, which at 3 weeks do not completely fill the embrasure spaces.



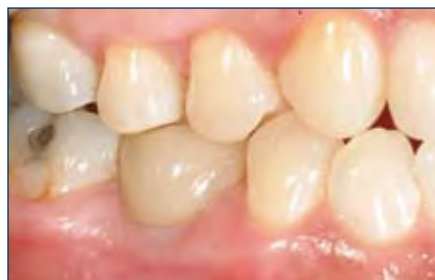**Figure 11** A final radiograph 3 weeks post-placement.



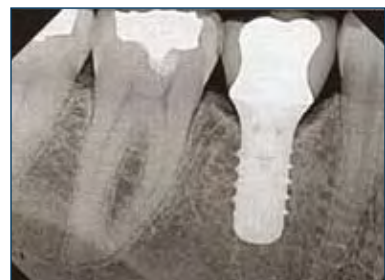**Figure 12** A view 6 months post-placement. Note the filling in of the soft tissues which has occurred in the interproximal spaces.



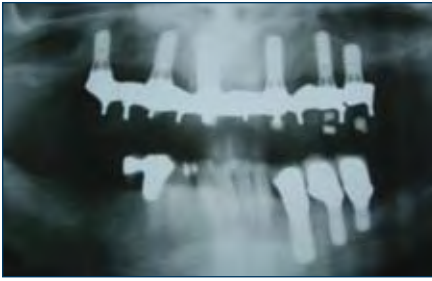**Figure 13** A 6 months post-implant placement view.



**Figure 14** A 2 years post-operative view. Note the stable, healthy soft tissue profile.



**Figure 15** A 2 years post-operative radiograph. Note the stable interproximal osseous levels.



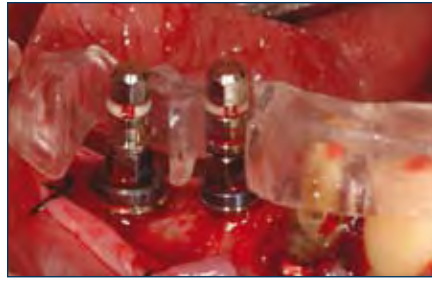**Figure 16** A radiographic view of the restored implants.

At up to 2.5 years post insertion all 25 implants were functioning successfully. DIB bone changes were minimal between examination periods, ranging from a loss of 0.65 mm to a gain of 0.4 mm (Figures 14-16).

### Discussion

Rocuzzo et al<sup>6</sup>, in a split mouth study, evaluated 2 implants in the same patient with the only variable being the surface characteristics (SLA and TPS surface), and early loading. They reported on 106 implants, and found 100% success at 5 years in both groups. Four “spinners” in the test group (SLA) which rotated upon abutment connection (35 Ncm torque delivered) at 6 weeks and were retested 6 weeks showed no differences at 5 years to the test implants loaded at 6 weeks. The occurrence of implant “spinners,” when properly handled, does not result in a detrimental clinical outcome.<sup>8,9</sup>

Oates et al.<sup>12</sup>, in a clinical study of 31 patients receiving SLA and SLActive implants, evaluated differences in resonance frequency analysis weekly for up to 6 weeks, and found a shift in implant stability from decreasing stability to increasing stability after two weeks for the SLActive implants and after 4 weeks with the SLA implants. This finding suggests a change in overall bone metabolism associated with the implant surface from predominately resorptive to predominately formative, indicating an enhanced healing process associated with the modified implant surface.<sup>12</sup> Similar short-term clinical success was observed with both implant surfaces, as all 62 implants were clinically successful and restored at 6 weeks, and confirmed by RFA. Seven mandibular implant “spinners” were noted, with 5/31 being in the SLA control group and 2/31 in the test group (6%). All “spinners” occurred between 1 and 4 weeks, and most occurred (4/7) at week 3. A significant change in the pattern of stability was noted for test implants at the 2-week time point in both the mandible and the maxillae, which was not evident in the control-SLA implants over the 6-week healing period.

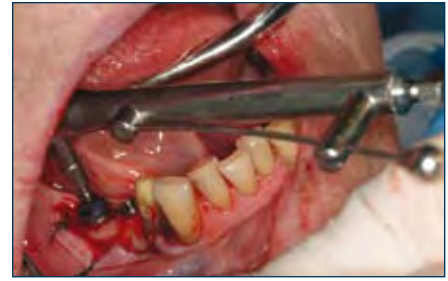

**Figure 17** Implants are placed utilizing a surgical guide.

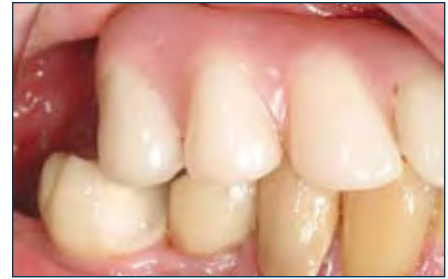The present study used insertion torque values of greater than or equal to 35 Ncm to determine entrance into the study. Four out of 25 (16%) of the implants “spun” or were uncomfortable to the patients at the 3-4 week appointments when the final crowns were to be delivered. An additional 6 weeks were allowed prior to restoration. No differences were noted in these implants radiographically and clinically. The crowns made for the 4 implants that were “spinners” were discarded, requiring new impressions and delivery of new crowns after re-torquing and bone healing was confirmed 6 weeks later. Two of the 4 “spinner” implants were in a 78-year old female with a history of osteoporosis (an 8 mm RN implant #29) and one was a case of a previously treated lateral wall sinus augmentation in the area of #4. The other 2 “spinners” were in a single patient, in a lower pre-molar region.

Although there is no agreed upon protocol available regarding early loading of SLActive single tooth implants, a suggested guide based on the present study would be to avoid excessive bone tapping prior to implant placement, and to only restore these cases immediately, upon attaining an initial torque value of at least 32 Ncm, or an implant stability quotient (ISQ) as measured by resonance frequency analysis, of over 609.<sup>11,23,24,28-33</sup>

The present 2.5 year study confirms that early restoration of SLActive posterior single tooth implants with good primary stability, as noted by insertion torque values of at least 35 Ncm, is a safe and predictable procedure. Patient benefits include improved esthetics, improved comfort and self-esteem, predictable space maintenance and soft-tissue sculpturing<sup>21,34-36</sup> of the definitive single crown restoration over time. The implant shoulder should be located slightly below the mucosal level to allow the final crown to shape the peri-implant soft tissues, as was shown to occur in the 6-12 months post-crown insertion. All team members need to be aware of their expected function in delivering the final, ideally contoured restoration.<sup>21-25</sup>



**Figure 18** The implants are placed to 35 Ncm of torque.



**Figure 19** A view of the restored implants.

### Conclusions

Based on this 2-year study, early final restoration of posterior single tooth implants with the hydrophilic chemically modified SLActive surface, placed in healed sites not requiring bone augmentation and restored after 3-4 weeks of healing, offers a means to attain predictable tissue integration if strict inclusion criteria are followed. This is a viable treatment option for healthy patients when good primary stability (>35 Ncm) is achieved at implant insertion. However, findings of interarch variations<sup>37</sup> in bone quality may affect implant stability, indicating the need for long-term studies with larger number of patients.

## References

1. Wilke HJ, Claes L, Steinmann S. **The influence of various titanium surfaces on the interface shear strength between implants in bone.** In: Heimke G, Slotesz U and Lee AJC, eds. *Advances in Biomaterials-Clinical Implant Materials 1990*; 9:309-314. Amsterdam: Elsevier Science Publishers BV.
2. Buser D, Schenk RK, Steinmann S, Fiorellini JP, Fox CH, Stich H. **Influence of surface characteristics on bone integration of titanium implants with a sandblasted and acid-etched surface: a bio-mechanical study in the maxilla of miniature pigs.** *Journal of Biomed Materials Res* 1991; 25: 889-902.
3. Cochran DL, Schenk RK, Lussi A, Higginbottom FL, Buser D. **Bone response to unloaded and loaded titanium implants with a sandblasted and acid-etched surface: a histometric study in the canine mandible.** *Journal of Biomed Materials Res* 1998; 40:1-11.
4. Buser D, Nydegger T, Oxland T, Cochran DL, Schenk RK, Hirt HP, Snetivy D, Nolte LP. **Interface shear strength of titanium implants with a sandblasted and acid-etched surface: a bio-mechanical study in the maxilla of miniature pigs.** *Journal of Biomed Materials Res* 1999; 45:75-83.
5. Cochran D, Buser D, ten Bruggenkate CM et al. **The use of reduced healing times on ITI implants with sandblasted and acid-etched (SLA) surface: Early results from clinical trials on ITI SLA implants.** *Clin Oral Impl Res* 2002; 13:144-153.
6. Rocuzzo M, Aglietta M, Bunino M, Bonino L. **Early loading of sandblasted and acid-etched implants: a randomized-controlled double-blind split-mouthed study. Five-year results.** *Clin Oral Impl Res* 2008; 19:148-152.
7. Cochran D, Oates T, Morton D, Jones A, Buser D, Peters F. **Clinical field trial examining an implant with a sand-blasted, acid-etched surface.** *Journal of Periodontol* 2007; 78:974-82.
8. Bornstein MM, Schmid B, Belser U, Lussi A, Buser D. **Early loading of non-submerged titanium implants with a sandblasted and acid-etched surface. 5-year results of a prospective study in partially edentulous patients.** *Clin Oral Impl Res* 2005; 16:63-638.
9. Salvi GE, Ballini G, Lang NP. **Early loading (2 or 6 weeks) of sandblasted and acid-etched (SLA) ITI implants in the posterior mandible. A 1-year randomized controlled clinical trial.** *Clin Oral Impl Res* 2004; 15:142-149.
10. Bornstein MM, Halbritter S, Harnisch H, Weber HP, Buser D. **A retrospective analysis of patients referred for implant placement to a specialty clinic: Indications, surgical procedures, and early failures.** *Int J Oral Maxillofac Implants* 2008; 23:1109-1116.
11. Cochran DL, Morton D, Weber HP. **Consensus statements and recommended clinical procedures regarding loading protocols for endosseous dental implants.** *Int J Oral Maxillofac Implants* 2004; 19 SUPPL:109-113.
12. Oates TW, Valderrama P, Bischof M, Nedir R, Jones A, Simpson J, Toutenburg H, Cochran DL. **Enhanced implant stability with a chemically modified SLA surface: a randomized pilot study.** *Int J Oral Maxillofac Implants* 2007; 22:755-760.
13. Zhao G, Schwartz Z, Wieland M, Rupp F, Geis-Gerstorfer J, Cochran DL, Boyan BD. **High surface energy enhances cell response to titanium substrate microstructure.** *Journal of Biomedical Materials Research Part A* 2005;74:49-58.
14. Rupp F, Scheideideler L, Olshanka N, de Wild M, Wieland M, Geis-Gerstorfer J. **Enhancing surface free energy and hydrophilicity through chemical modification of microstructured titanium implant surfaces.** *Journal of Biomedical Materials Research Part A* 2005;76:323-334.
15. Buser D, Broggin N, Wieland M, Schenk RK, Denzer AJ, Cochran DL, Hoffman B, Lussi A, Steinemann S. **Enhanced bone apposition to a chemically modified SLA titanium surface.** *J Dent Res* 2004;83:529-533.
16. Bornstein MM, Valderrama P, Jones AJ, Wilson TG, Seibl R, Cochran DL. **Bone apposition around two different sandblasted and acid-etched titanium implant surfaces: a histomorphometric study in canine mandibles.** *Clin Oral Impl Res* 2008;19:233-241.
17. Ferguson SJ, Broggin N, Wieland M, de Wild M, Rupp F, Geis-Gerstorfer J, Cochran DL, Buser D. **Biomechanical evaluation of the interfacial strength of a chemically modified sandblasted and acid-etched titanium surface.** *Journal of Biomedical Materials Research Part A* 2006;78:291-297.
18. Schwarz F, Herten M, Sager M, Wieland M, Dard M, Becker J. **Histological and immunohistochemical analysis of initial and early osseous integration at chemically modified and conventional SLA titanium implants: preliminary results of a pilot study in dogs.** *Clinical Oral Implants Res* 2000; 18:481-488.
19. Schwarz F, Herten M, Sager M, Wieland M, Dard M, Becker J. **Histological and immunohistochemical analysis of initial and early subepithelial connective tissue attachment at chemically modified and conventional SLA titanium implants. A pilot study in dogs.** *Clinical Oral Investigations* 2007;11:245-255.
20. Ganeles J, Zollner A, Jackowski J, ten Bruggenkate, Beagle J, Guerra F. **Immediate and early loading of Straumann implants with a chemically modified surface (SLActive) in the posterior mandible and maxilla: 1-year results from a prospective multicenter study.** *Clin Oral Impl Res* 2008; 19: 1119-1128.
21. Ganeles J, Wismeijer D. **Early and immediately restored and loaded dental implants for single-tooth and partial-arch applications.** *Int J Oral Maxillofac Impl* 2004; 19(Suppl): 92-102.
22. Morton D, Jaffin R, Weber HP. **Immediate restoration and loading of dental implants: clinical considerations and protocols.** *Int J Oral Maxillofac Impl* 2004; 19 (Suppl); 19: 103-108.
23. Levine RA, Shulman DA, Burns R. **Mandibular arch immediate implant loading using a modified-SLA surface. A series of 21 cases in a private periodontal practice incorporating an interdisciplinary team approach: Clinical technique and laboratory protocol.** *Functional esthetics and restorative dentistry* 2008; series 2 (#3):2-11.
24. Levine R, Makrauer Z, Burns. **Straumann® SLActive and immediate loading: decreasing time while increasing confidence.** *Target* 2008;1: 41-46.
25. Buser D, Martin W, Belser UC. **Optimizing esthetics for implant restorations in the anterior maxillae: anatomic and surgical considerations.** *Int J Oral Maxillofac Impl* 2004; 19 (Suppl); 19:43-61.
26. Buser D, von Arx T. **Surgical procedures in partially edentulous patients with ITI implants.** *Clin Oral Implants Res* 2000;11(Suppl):83-100.
27. Buser D, Weber HP, Lang NP. **Tissue integration of non-submerged implants. 1-year results of a prospective study with 100 ITI hollow-cylinder and hollow-screw implants.** *Clin Implant Dent Relat Res* 1990; 1:33-40.
28. Wöhrle P. **Single-tooth replacement in the esthetic zone with immediate provisionalization: 14 consecutive case reports.** *Prac Proced Aesth Dent.* 1998;10:1107-1114.
29. Callandriello R, Tomatis M, Rangert B. **Immediate functional loading of Branemark System implants with enhanced initial stability: a prospective 1-2-year clinical and radiographic study.** *Clin Implant Dent Relat Res* 2003; 5 (Suppl)1:10-20.
30. Ottoni, Olivera, Mansini, Cabral. **Correlation between placement torque and survival of single-tooth implants.** *Int J Oral Maxillofac Impl* 2005; 20:769-776.
31. Payer M, Kirmeier R, Jakse N, Wimmer G, Wegscheider W, Lorenzoni M. **Immediate provisional restoration of XIVE® screw-type implants in the posterior mandible.** *Clin Oral Impl Res* 2008; 19:160-165.
32. Guncu MB, Aslan Y, Tumer C, Guncu GN, Uysal S. **In-patient comparison of immediate and conventional loaded implants in mandibular molar sites within 12 months.** *Clin Oral Impl Res* 2008; 19:335-341.

- <sup>33.</sup> Bornstein MM, Hart CN, Halbritter SA, Morton D, Buser D. **Early loading of nonsubmerged titanium implants with a chemically modified sand-blasted and acid-etched surface: 6-month results of a prospective case series study in the posterior mandible focusing on peri-implant crestal bone changes and implant stability quotient (ISQ) values.** *Accepted to Clinical Implant and Related Research 2009.*
- <sup>34.</sup> Abboud M, Koeck B, Stark H, Wahl G, Paillon R. **Immediate loading of single-tooth implants in the posterior region.** *Int J Oral Maxillofac Impl 2005; 20: 61-68.*
- <sup>35.</sup> Gallucci GO, Mavropoulos A, Bernard J-P, Belser UC. **Influence of immediate implant loading on peri-implant soft tissue morphology in the edentulous maxilla.** *Int J Oral Maxillofac Impl 2007;22:595-602.*
- <sup>36.</sup> Levine RA. **Immediate restoration of single-tooth implants in mandibular molar sites in a private practice-survival rates at 5 years. In manuscript. 2009. To be submitted to Int J Oral Maxillofac Impl.**
- <sup>37.</sup> Bischof M, Nedir R, Szmuckler-Moncler S, Bernard JP, Samson J. **Implant stability measurement of delayed and immediately loaded implants during healing.** *Clin Oral Implants Res 2004;15:529-539.*



**Nadine Brodala, DDS, MS** is an Assistant Professor in the Department of Periodontology at UNC. She received her DDS degree from the Philipps Universität Marburg, Germany. In 2002, she graduated from UNC with a Certificate and MS in Periodontology. Dr. Brodala received the coveted Orban Prize granted by the American Academy of Periodontology for her research thesis. She received the degree of Dr med dent (PhD) for her dissertation from the Philipps-Universität Marburg. Dr. Brodala became a Diplomate of the American Academy of Periodontology in 2004. In 2006 she became the Director of the ITI Implant Scholarship at UNC, and the title of an ITI fellow was granted to her in 2007. She has maintained a clinical practice limited to Periodontology and Implantology since 2003.

## The Interdisciplinary Treatment of Patients with Hypodontia and Oligodontia

According to a 1996 Consensus Conference on Oral Implants in Young Patients<sup>1</sup>, the following definitions are used to describe the congenital absence of permanent teeth: 'hypodontia' is defined as the absence of one to five permanent teeth; while the term 'oligodontia' denotes the absence of six or more permanent teeth and 'anodontia' refers to the developmental absence of all permanent teeth. This developmental absence of teeth is usually discovered radiographically.<sup>2</sup>

The incidence rates among Europeans given for the congenital absence of one to five teeth (hypodontia) range between 0.3% and 13.6%, excluding third molars.<sup>3,4</sup> Oligodontia, the absence of 6 or more teeth, is a less common disorder, and can be described as an isolated form (Oligodontia-I) or as part of a syndrome (Oligodontia -S), such as in ectodermal dysplasia.<sup>5,6</sup> Its incidence rate in the European population is 0.08%. Anodontia is encountered in an even smaller percentage of patients. There is a female predisposition noted in the appearance (1.5:1) of congenitally missing teeth.

The etiology of the congenital absence of teeth has been shown to be heredity or developmental anomalies.<sup>5</sup> Genetic influences might affect non-syndromic numeric alterations of teeth, as more than 200 genes are known to play a specific role in odontogenesis. In addition, the environment

illustrates its influence in these developmental alterations, suggesting multifactorial inheritance patterns. Thus, hypodontia most likely presents a variety of disorders caused by variable genetic and epigenetic factors.<sup>7</sup> Hypodontia and oligodontia correlate with the absence of appropriate dental lamina. This lamina is sensitive to external stimuli. Its damage before tooth formation has been shown to lead to hypodontia. Trauma, radiation, infection, chemotherapeutic medications, endocrine disturbances, and severe intrauterine disturbances have been associated with missing teeth.<sup>7</sup>

The congenital absence of permanent teeth has certain anatomic implications, as the development of the alveolar process via local apposition of bone requires the presence of local teeth.<sup>8,9</sup> As the dentition is essential to the formation of the maxillary and mandibular alveolar processes, the congenital absence of a large number of teeth results in a decrease in growth stimuli to the jawbone.<sup>10,11</sup> This leads to a local bone deficiency, and inhibits development of the entire bony masticatory apparatus.

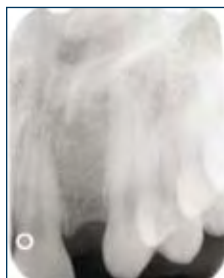
The most common clinical consequences resulting from this defective development are retained deciduous teeth, displacement of existing permanent teeth, false diastemata, impaired growth of the alveolar processes, pseudognathism, and a deep bite.<sup>12</sup>

The treatment of patients with hypodontia varies from person to person, as treatment options include space closure with orthodontic therapy, removable appliances, fixed tooth-borne prosthodontic restorations, dental implants, or a combination of these therapies. Thus, the ideal treatment should include a multidisciplinary team approach, with the interaction of the orthodontist, restorative dentist, and surgeon. Moreover, these patients present a special challenge as the height<sup>10</sup> and width<sup>13</sup> of the alveolar bone do not develop normally, as previously discussed. To further complicate the issue, the remaining permanent teeth are often malformed and smaller than usual.

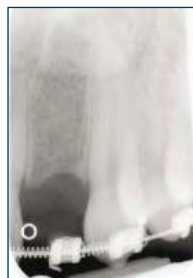
The following cases denote the approaches of a multidisciplinary team to treat several patients presenting with non-syndromal hypodontia and oligodontia.

### Case Report 1

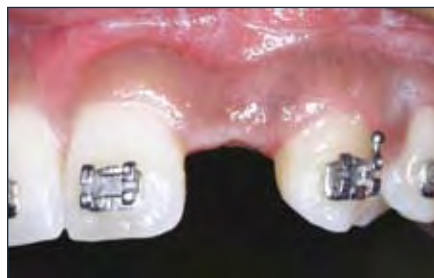A 23-year old female presented with a mild form of hypodontia. She was congenitally missing tooth #10. At the initial presentation a somewhat limited spacing of 4 mm was evident in the edentulous space (Figure 1). Thus, the first part of the treatment consisted of minor orthodontic treatment to correct the limited occlusal spacing (Figure 2). After a few months of treatment, ideal spacing was achieved and implant placement was



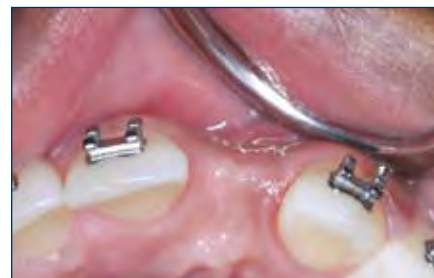**Figure 1** A pre-treatment periapical radiograph of the area of the congenitally missing tooth #10.



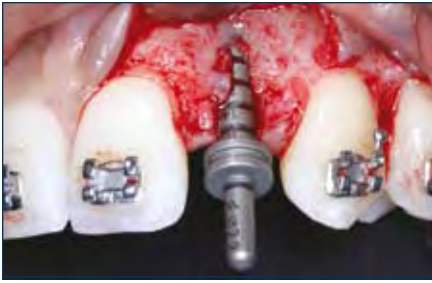**Figure 2** An intra-orthodontic treatment periapical radiograph of area #10.



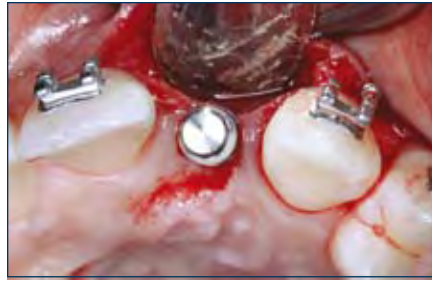**Figure 3a** A pre-operative facial view.



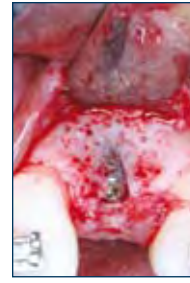**Figure 3b** A pre-operative occlusal view.



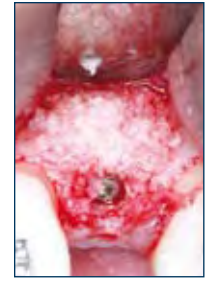**Figure 3c** 2.8 mm guide pin demonstrates facial bony defect.



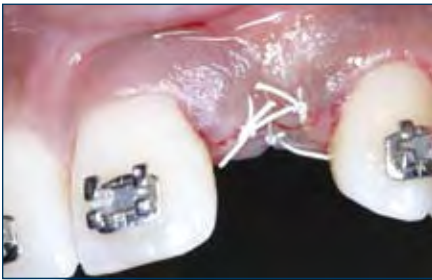**Figure 3d** An occlusal view of a placed Straumann Bone Level, Narrow Connection implant.



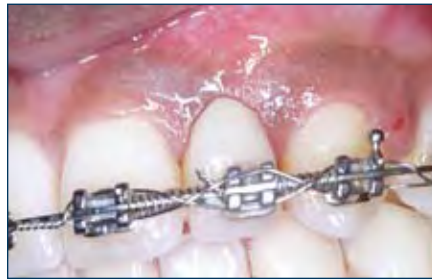**Figure 3e** A dehiscence is noted on the facial aspect of the implant.



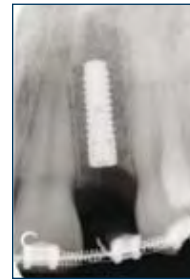**Figure 3f** Mineralized Allograft material is placed.



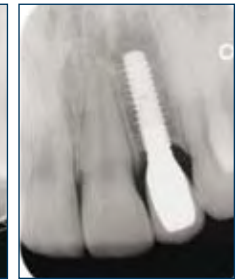
**Figure 3g** The flaps are repositioned.



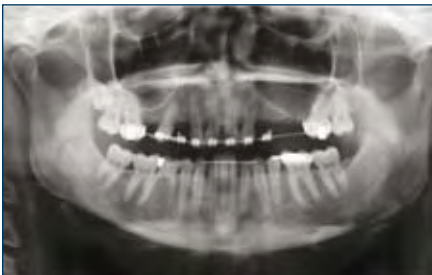**Figure 4a** 1 week post-operative view.



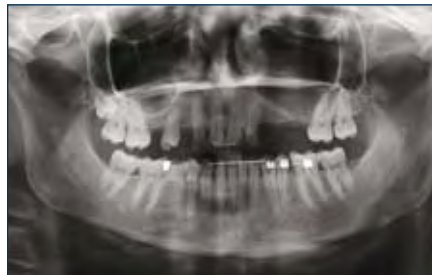**Figure 4b** A periapical radiograph of the implant in place.



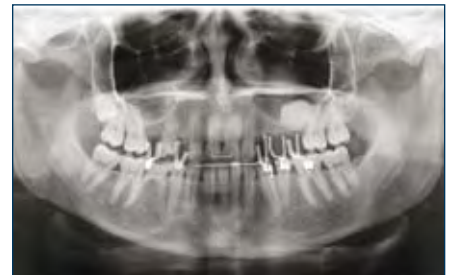**Figure 5** A periapical radiograph of final implant supported prosthesis.



**Figure 6a** A panoramic radiograph at the initiation of orthodontic treatment.



**Figure 6b** A panoramic radiograph at the end of active orthodontic treatment.



**Figure 6c** A panoramic radiograph after sinus augmentation effected in the left posterior sextant.

performed (Figures 3a-d). At time of implant placement a minor bony dehiscence was noted. It was grafted with mineralized allograft material and covered with a resorbable collagen membrane (Figures 3e-g). Post-operative healing was uneventful (Figures 4 a-b). After 3 months of further healing the final restoration was delivered (Figures 5 a-b).

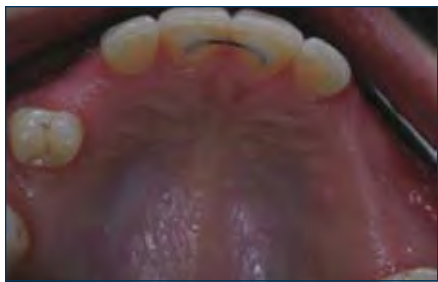### Case Report 2

A 35-year old female, presented with diagnosed oligodontia. She was congenitally missing teeth #4,6,11,12,13, and 29 (Figure 6a). The deciduous tooth T was present and asymptomatic. The consensus between patient, surgeon, and the prosthodontist was to keep T at this point in time.

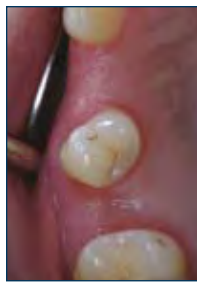The deciduous teeth in the positions of the aforementioned permanent teeth had been extracted over the past few years, and the patient was provided with a Removable Partial

Denture to replace the missing teeth. She was now interested in implant therapy to replace her missing teeth.

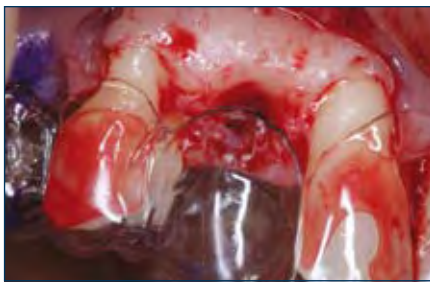After orthodontic treatment to attain more ideal tooth positioning, a sinus augmentation procedure was performed in the maxillary left quadrant (Figures 6b-c). After sufficient healing time (6 months) implant surgery was performed with appropriate surgical guides (Figures 7-15). After a few months of temporization to effect further soft tissue guided healing, and profiling, the final restorations were delivered.



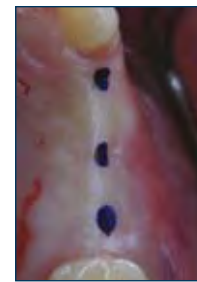**Figure 7** A pre-operative maxillary occlusal view.



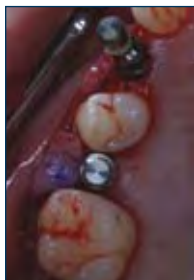**Figure 8** A pre-operative view of the maxillary right quadrant.



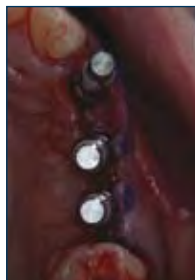**Figure 9** The surgical stent depicts the marginal contours of the planned crowns.



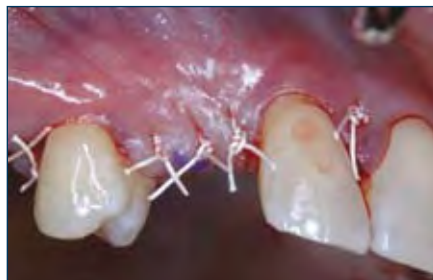**Figure 10** A pre-operative view of the maxillary left quadrant.



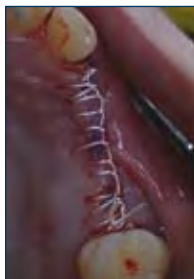**Figure 11** Implants are placed in the maxillary right quadrant.



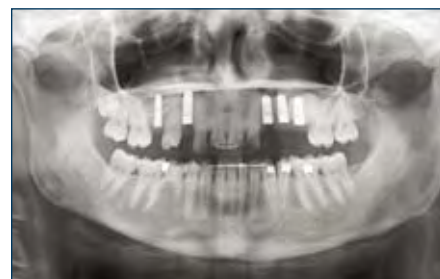**Figure 12** Implants are placed in the maxillary left quadrant.



**Figure 13** The maxillary right quadrant is sutured.



**Figure 14** The maxillary left quadrant is sutured.



**Figure 15** A post-operative panoramic radiograph.

## References

1. Koch G, Bergendal T, Kvint S, Johannsson UB (eds). **Consensus Conference on Oral Implants in Young Patients.** Jönköping, Sweden: The Institute for Postgraduate Dental Education 1996.
2. Wagenberg BD, Spitzer DA. **Therapy for a patient with oligodontia: Case report.** *J Periodontol* 2000;71:510-516.
3. Güzelow HJ, Pters R. **Zur Epidemiologie der Zahnunterzahl im bleibenden Gebiss.** *Dtsch Zahnärztl Z* 1977;32:545-549.
4. Rølling S. **Hypodontia of permanent teeth in Danish school children.** *Scand J Dent Res* 1980;88:365-369.
5. Schalk van der Weide Y. **Oligodontia. A clinical, radiographic and genetic evaluation. (thesis).** Utrecht: University of Utrecht, 1992.
6. Schalk von der Weide Y, Beemer FA. **Symptomatology of patients with oligodontia.** *J Oral Rehabil* 1994;21:247-261.
7. Neville BW, Damm DD, Allen CM, Bouquot JE. In: *Oral and Maxillofacial Pathology.* St. Louis: Saunders Elsevier Inc.;2009:77-82.
8. Moorrees CFA. **The dentition of the growing child. A longitudinal study of dental development between 3 and 18 years of age.** Cambridge: Harvard University Press, 1959.
9. Van der Linden FPGM, Duterloo HS. **Development of the Human Dentition. An Atlas.** New York: Harper & Row, 1976.
10. Sarnäs KV, Rune B. **The facial profile in advanced hypodontia.** *Eur J Orthod* 1983;5:133-143.
11. Bergendal T, Eckerdal O, Hallonsten AL, Koch G, Kurol J, Kvint S. **Osseointegrated implants in oral habilitation of a boy with ectodermal dysplasia: A case report.** *Int Dent J* 1991;41:149-156.
12. Kloepfel JG. **The Größenentwicklung des Oberkiefers bei Fällen von Zahnunterzah.** *Fortschr Kieferorthop* 1957;18:85-89.
13. Hobkirk JA, Brook AH. **The management of patients with severe hypodontia.** *J Oral Rehabil* 1980;7:289-298.





**Dean Morton, BDS, MS** is a Professor in the Department of Diagnostic Sciences, Prosthodontics and Restorative Dentistry at the University of Louisville School of Dentistry, and Assistant Dean for Multidisciplinary Implant and Esthetic Dentistry. Dr. Morton is a Diplomate of the American Board of Prosthodontics. He is a Fellow or member the American College of Prosthodontists, International College of Dentists, and the International Team for Implantology (ITI). He is also a consultant for the ADA Commission on Dental Accreditation, and is a reviewer for several scientific publications including the Journal of Periodontology and the Journal of Prosthodontics. He has previously served on the editorial boards of the Journal of Prosthetic Dentistry and International Journal of Oral and Maxillofacial Implants. Dr. Morton has authored or co-authored more than 40 scientific articles and abstracts. He was the primary author of the ITI Treatment Guide, Vol. 2, Loading Protocols in Implant Dentistry, and a contributing author of the ITI Treatment Guide, Vol. 1. Dr. Morton lectures extensively both nationally and internationally on implants and esthetic dentistry. He maintains a practice limited to Implant and Esthetic Dentistry and Prosthodontics at the University of Louisville School of Dentistry.

## Loading Protocols for Completely and Partially Edentulous Patients

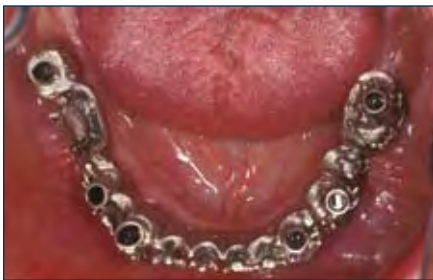Dental implants have been successfully incorporated into dental treatment for more than forty years. Initially, placement and loading protocols were advocated to ensure the survival of the implants in bone – i.e. the maintenance of osseointegration or functional ankylosis was paramount.<sup>1,3</sup> Placement of implants into healed sites in both arches, combined with loading protocols maintaining 3-6 months of undisturbed implant healing subsequent to placement, resulted in a high degree of implant survival.<sup>4,5</sup>

In both clinical practice and scientific literature, survival of the implant became synonymous with treatment success. However, the time required to complete care remained lengthy. Consequently, implant placement and loading protocols for patients began to be scrutinized. Furthermore, while treatment protocols were initially designed for the treatment of mandibular edentulism with

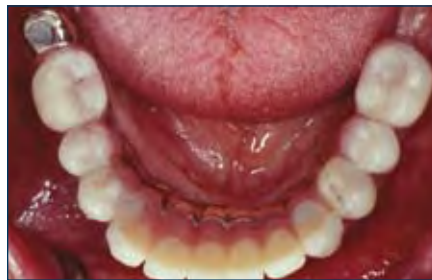cross-arch splinting (Figures 1-6), clinical success led to a rapid incorporation of implants in the treatment of maxillary and partial edentulism (Figures 7-12).

Concurrent with this scrutiny, it became recognized that dental implants survive in a range of placement and loading protocols, for the most part when certain conditions are satisfied. These conditions include:

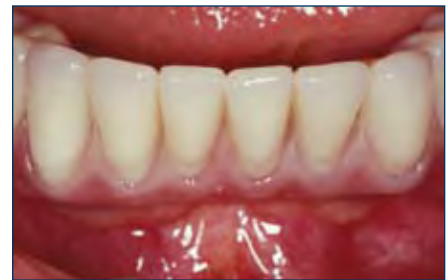1. The procedures are performed by clinicians with the appropriate levels of education, skill and experience for the chosen procedure. This topic has been considered in detail in a recently published text, 'The SAC Classification in Implant Dentistry'.
2. The patient is in good health, both systemically and locally, and capable of undergoing the chosen treatment procedures.
3. Adequate volume and quality of bone are present into which implants can be positioned (this bone could be native and/or grafted).
4. The implant chosen is characterized by modern, evidence-based design features, including shape, material, connection type and surface character. Implant survival is now considered only one component of treatment success. The purpose of the dental implant (to support, stabilize and retain a dental prosthesis) is more routinely evaluated. It has become insufficient to consider integration alone as criteria for determining treatment success. Functional and esthetic satisfaction are central to assessment of treatment outcomes, and the demand for timely and efficient therapy has rightfully increased.



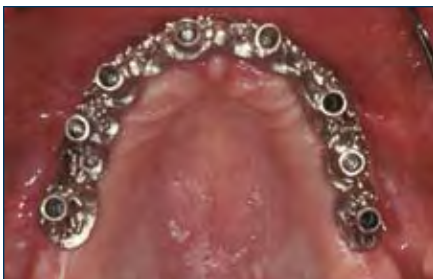**Figure 1** A view of conventional loading with a mandibular framework.



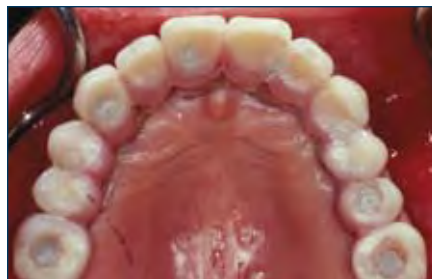**Figure 2** A view of conventional loading with the definitive mandibular prosthesis in place.



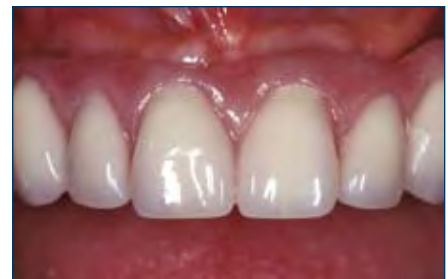**Figure 3** A view of the definitive mandibular prosthesis.



**Figure 4** A view of conventional loading with a maxillary framework.



**Figure 5** A view of conventional loading with the definitive maxillary prosthesis in place.



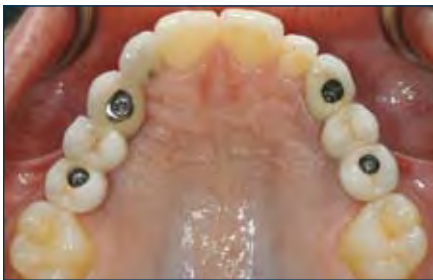**Figure 6** A view of the definitive maxillary prosthesis.

In the last decade or so manufacturers have introduced implants with specifically roughened surfaces to accelerate treatment without elevating the likelihood of a compromised outcome. These surfaces, (most notably SLA<sup>®</sup> and SLActive<sup>®</sup>) obtain implant stability capable of withstanding oral forces earlier than implants characterized by machined or early form roughened surfaces. For the majority of patients (bone types I-III) the introduction of these surfaces resulted in markedly reduced treatment times. The period of undisturbed healing recommended for the implants was halved to between 6 and 8 weeks.<sup>6-12</sup> The continued success of therapy with these shortened treatment times has been well documented. Placement and loading alternatives for dental implants were evaluated as part of the ITI Consensus Conferences held in Gstaad, Switzerland, in 2003. The recommended loading protocols were summarized in Consensus documents published in 2004.<sup>13-16</sup>

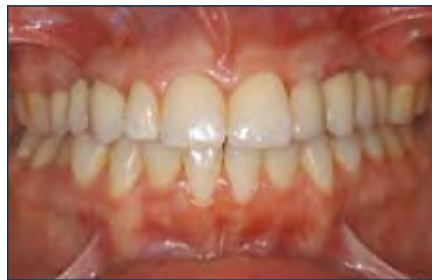Pressure (both from the market and the scientific community) has continued to grow to further shorten healing periods and overall treatment times. While remaining a noteworthy goal of therapy, initial proposals for further routine reductions in loading protocols (immediate protocols and less than six weeks) were mostly unsubstantiated by scientific evidence. Efforts were made, to improve documentation for these loading protocols. This has mostly been

achieved through prospective clinical cohort evaluations, and early and immediate loading protocols have become treatment options with an improving scientific basis. Loading protocols were re-evaluated by the ITI in the most recent Consensus Conference held in Stuttgart, Germany, in 2008. Updated statements and recommendations have been developed, and submitted for publication as part of the Consensus proceedings.

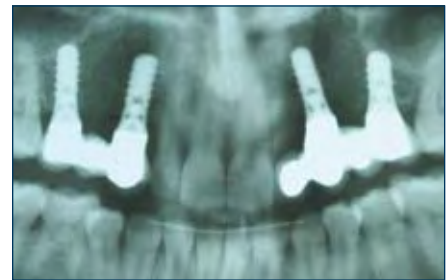The most pressing concern with regard to accelerated loading protocols is not the treatment outcome. Rather, the most pressing concern remains the quality and volume of scientific evidence gathered to support the clinical procedures being advocated. Throughout the years rigid criteria have been applied to evaluation of the science supporting procedures – the quality of the evidence. While certainly admirable, more recently there has been a shift to include meaningful information from publications generally considered of lesser quality. The absence of randomized clinical trials and systematic reviews to support treatment options is typically the case in implant dentistry. However, critical evaluation of existing literature still enables the profession to glean information that is both meaningful and useful in the formulation of recommendations for implant loading protocols.



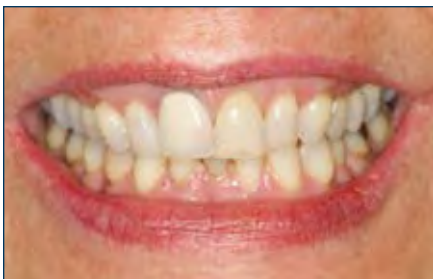**Figure 7** A view of early (6 week) loading.



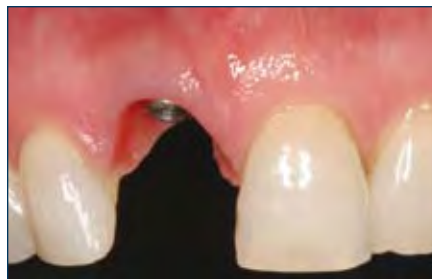**Figure 8** An anterior view of early (6 week) loading.



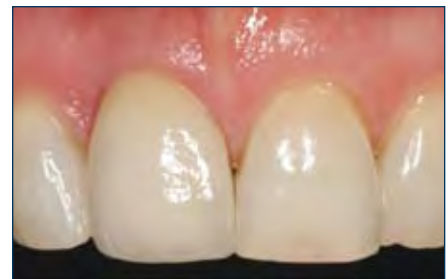**Figure 9** A radiograph of early loading.



**Figure 10** A pre-treatment view, where early loading is to be utilized in replacement of a single central incisor.



**Figure 11** A view of soft tissue development with early loading.




**Figure 12** A view of the definitive restoration on a central incisor following early loading.

## References

1. Brånemark PI, Adell R, Breine U, Hansson BO, Lindström J & Ohlsson A. **Intraosseous anchorage of dental prostheses. I. Experimental studies.** *Scandinavian Journal of Plastic and Reconstructive Surgery* 1969; 3: 81–100.
2. Brånemark PI, Hansson BO, Adell R, Breine U, Lindström J, Hallen O & Ohman A. **Osseointegrated implants in the treatment of the edentulous jaw. Experience from a 10-year period.** *Scandinavian Journal of Plastic and Reconstructive Surgery* 1977; 16 (Suppl.): 1–132.
3. Schroeder A, van der Zypen, E Stich H & Sutter F. **The reaction of bone, connective tissue and epithelium to endosteal implants with titanium-sprayed surfaces.** *Journal of Maxillofacial Surgery* 1981; 9: 15–25.
4. Adell R, Eriksson B, Lekholm U, Brånemark PI, Jemt T. **Long-term follow-up study of osseointegrated implants in the treatment of totally edentulous jaws.** *Int J Oral Maxillofac Implants* 1990; 5:347-359.
5. Zarb GA, Schmitt A. **The longitudinal clinical effectiveness of osseointegrated dental implants: the Toronto study. Part I: Surgical results.** *J Prosthet Dent* 1990; 63:451-457.
6. Rocuzzo M, Bunino M, Prioglio F & Bianchi SD. **Early loading of sandblasted and acid-etched (SLA) implants: a prospective split-mouth comparative study.** *Clinical Oral Implants Research* 2001; 12: 572–578.
7. Romeo E, Chiapasco M, Ghisolfi M & Vogel G. **Long-term clinical effectiveness of oral implants in the treatment of partial edentulism. Seven-year life table analysis of a prospective study with ITI® Dental Implants System used for single-tooth restorations.** *Clinical Oral Implants Research* 2002; 12: 133–143.
8. Cochran DL, Buser D, ten Bruggenkate CM, Weingart D, Taylor TM, Bernard JP, Peters F & Simpson JP. **The use of reduced healing times on ITI implants with a sandblasted and acid-etched (SLA) surface: early results from clinical trials on ITI SLA implants.** *Clinical Oral Implants Research* 2002; 13: 144–153.
9. Rocuzzo M & Wilson TG. **A prospective study evaluating a protocol for 6 weeks' loading of SLA implants in the posterior maxilla.** *Clinical Oral Implants Research* 2002; 13: 502–507.
10. Bornstein MM, Lussi A, Schmid B, Buser UC & Buser D. **Early loading of titanium implants with a sandblasted and acid-etched (SLA) surface: 3-year results of a prospective study in partially edentulous patients.** *International Journal of Oral & Maxillofacial Implants* 2003; 18: 659–666.
11. Salvi GE, Gallini G & Lang NP. **Early loading (2 or 6 weeks) of sandblasted and acid-etched (SLA) ITI® implants in the posterior mandible. A 1-year randomized controlled clinical trial.** *Clinical Oral Implants Research* 2004; 15: 142–149.
12. Cochran D, Oates T, Morton D, Jones A, Buser D, Peters F. **Clinical field trial examining an implant with a sand-blasted, acid-etched surface.** *J Periodontol* 2007; 78: 974-982.
13. Chiapasco, M. **Early and immediate restoration and loading of implants in completely edentulous arches.** *Int J Oral Maxillofac Implants* 2004; 19(Suppl): 76-91.
14. Ganeles J, Wismeijer D. **Early and immediately restored and loaded dental implants for single-tooth and partial-arch applications.** *Int J Oral Maxillofac Implants* 2004; 19(Suppl); 92-102.
15. Morton D, Jaffin R, Weber HP. **Immediate restoration and loading of dental implants: Clinical considerations and protocols.** *Int J Oral Maxillofac Implants* 2004; 19(Suppl); 103-108.
16. Cochran DL, Morton D, Weber HP. **Consensus statements and recommended clinical procedures regarding loading protocols for endosseous dental implants.** *Int J Oral Maxillofac Implants* 2004; 19(Suppl); 109-113.





**Vincent W. Meng, DDS, PC** graduated from the University of Illinois College of Dentistry in 1977, and then completed a residency program in general dentistry at Illinois Research Hospital in Chicago. At the University of Illinois, he served as an instructor in comprehensive clinical dentistry and was a clinician and Director of the Department of Dentistry at Franklin Boulevard Community Hospital. Dr. Meng is also a Fellow in the American College of Dentists, and the International Team of Implantology (ITI). Other accomplishments include: The Clinical Excellence Award from the Montana Dental Association in 1999 where he was the 10th recipient of this lifetime achievement award, which is given for clinical excellence and the promotion and support of continuing dental education in Montana. He currently maintains a private practice in Missoula, Montana.

## Achieving Maximum Esthetic Results through Proper Laboratory Communication

The value of the team approach in achieving predictable and successful results with implant restorations, particularly in the esthetic zone is well recognized. One of the often overlooked members of the dental team is the dental laboratory technician. The product of the dental laboratory is only as good as a well designed and communicated esthetic plan. Anterior esthetic restorations are often the least profitable prosthetic procedure, even when all the steps go smoothly. An error causing a return to the dental laboratory further reduces productivity.

### Keys to Communicating the Esthetic Plan

- Transitional restorations that fit the esthetic plan
- Records and guides to communicate all critical aspects of the case
- Color corrected photographs in PowerPoint to explain all aspects of commonly accepted esthetic principles, including: tooth position and proportion, tissue level, arrangement, shape and texture, contour, and color.

In order to communicate these principles, a brief discussion of commonly accepted esthetic principles is appropriate. Numerous articles have been written, describing esthetic principles in the esthetic zone.

A common technique, as described by Spear and others, includes first determining resting

lip position (Figure 1). This is the amount of tooth display of the central incisors with the mouth open and the lips at rest, and this generally varies from 1 to 3 mm depending on age, sex, and lip mobility. Once this position is established other parameters can systematically be determined starting with dental midline, tooth position, tooth proportion, tissue level, arrangement, shape and color. As described by Kokich, the dental midline can vary by 3 to 4 mm and still appear clinically acceptable to lay people if the long axes of the teeth are parallel to the long axis of the face. Figure 2 shows a 2 mm midline shift to the right that would still meet acceptability. When evaluating tooth position, positioning the labial surface of central incisors perpendicular to the posterior maxillary occlusal plane will result in light reflecting the surface characteristics in a pleasing fashion (Figure 3).

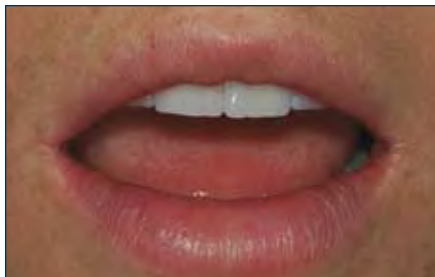The proportion of teeth has been defined in many forms, such as the Golden proportion. However, this proportion is found to be accurate for the natural dentition only eighteen percent of the time. More recent descriptions by Steven Chu and others, based on measurements of the natural dentition of various ethnic groups, more accurately describe a proportion common to all these groups. If the central incisor width is (X) mm, the lateral incisor width is X-2mm and canine width is X-1 mm. The width to height ratio is approximately eighty percent.

This proportion gives a logical position for the tissue level by measuring up from the

predetermined incisal edge. The arrangement of the teeth must then appropriately fill the available space. Small space deficiencies can be managed with minor rotations, but larger deficiencies or space excess may require consideration of additional restorative dentistry, orthodontics or both. Also described by Kokich, deviations from the normal are still often acceptable to the lay person as long as the deviations are symmetrical. Figure 3 also shows a lower tissue level (and width/height ratio) that would still be considered acceptable.

If the dental laboratory is made aware of these esthetic parameters, they will more consistently value the information provided to them. Addressing all of the above esthetic issues, even in single tooth situations, is valuable, as additional restorative dentistry or minor bonding procedures will frequently yield a more acceptable end result. When patients are provided this information prior to treatment, they will usually make better choices about their treatment plan than if esthetic problems are encountered in the transitional fabrication phase. Figures 4 and 5 demonstrate the value of additional restorative dentistry if over only restoration of the tissue level single implant crown on tooth #8. Using an Straumann CAD/CAM milled zirconium core on #8 and Straumann CAD/CAM zirconium based crown on #9 provided harmony with veneers on #'s 7 and 10. Increased incisal length would not have been possible with a single tooth restoration.

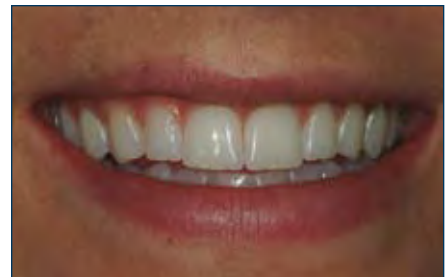The next important step is capturing the



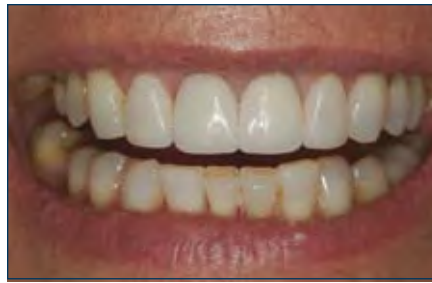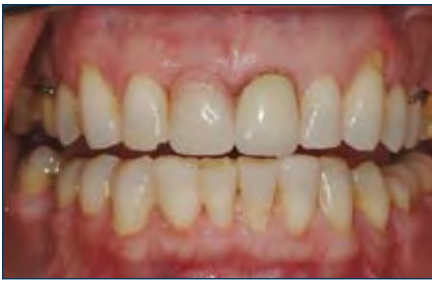**Figure 1** The resting lip is important to help determine the other esthetic parameters.



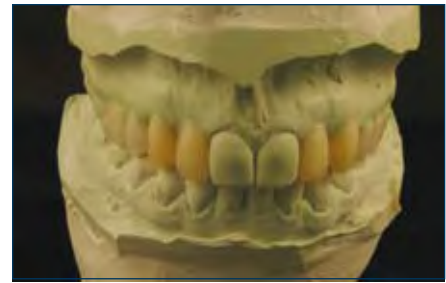**Figure 2** A midline shift is often non discernable when parallel to the facial plane.



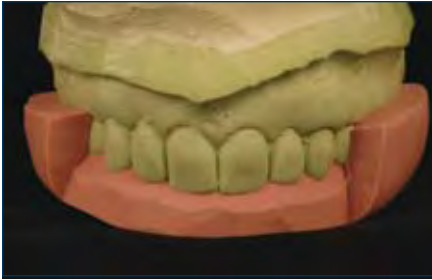
**Figure 3** A disproportional tissue level is frequently acceptable when it is symmetrical.



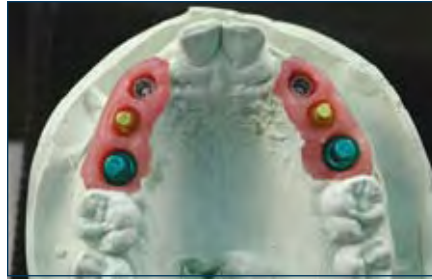**Figures 4, 5** Additional restorative dentistry more appropriately addresses esthetic demands than if only the tissue level single implant crown on tooth #8 was restored.



**Figure 6** When replacing multiple missing teeth, denture teeth will frequently simplify the diagnostic wax up.

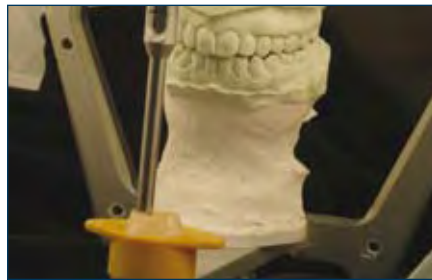
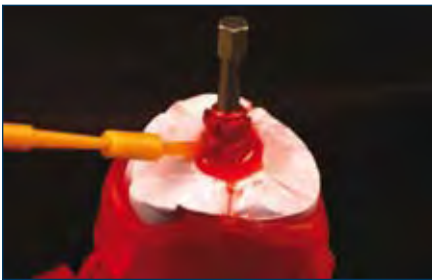
**Figure 7** A putty index of the transitional model will verify incisal edge positions of the final restorations.



**Figure 8** The tissue mask on the working model allows the technician to duplicate subgingival contours and margins of a potential coping.

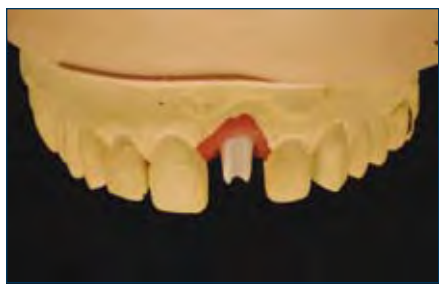above goals in the diagnostic wax up. Whether the laboratory technician or the restorative dentist performs the procedure, a PowerPoint with photographs of the close up smile, of front and lateral views, and a full face view photo are helpful to know how the teeth fit with the lips and face. Figure 6 demonstrates that replacement of multiple missing maxillary bicuspids, canines and lateral incisors. Utilizing denture teeth frequently simplifies the laboratory procedure, as contouring of the dentiform and/or wax addition can be performed to achieve ideal contours. Verification of occlusal compatibility in all excursive movements is essential on the articulated casts. Using a copy of this model for the surgical stent, the surgeon is committed to a well designed plan that he can verify using appropriate scans.



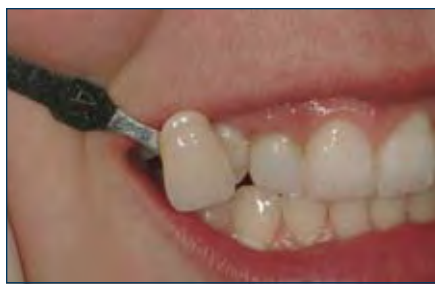**Figures 9-12** The additional polyvinyl index of the transitional can also be used to form a custom impression coping and fabrication of wax-up for cad-cam scanning and production of a custom milled core.

The clinical achievement of ideal transitional restorations in both the supragingival and subgingival areas is essential to give the laboratory a working blueprint for the final restoration. Supragingival contours are captured with a solid model (Figure 7) and photographs. A putty index of the model will verify incisal edge positions of the final restorations. Subgingival contours are often communicated using two indices. Figure 8, using a tissue mask in the peri-implant tissue area of the model, allows for duplication of this critical contour.

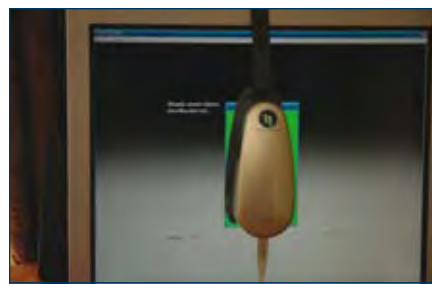
A separate guide fabricated chairside (Figures 9,10) by placing a lab analog on the temporary restoration and inserting it into a polyvinyl bite putty gives the laboratory technician an easy guide to wax up for either a cast subgingival component, or for scanning to incorporate a milled metal or zirconium understructure, such as when utilizing the Straumann CAD/CAM System. The separate analog can also be utilized to customize the impression coping so that the final working model with the tissue mask exactly mimics the tissue height and contour. Hence, the wax up will place the margin in an appropriate position. Improper margin placement of the coping would result in either a cement margin



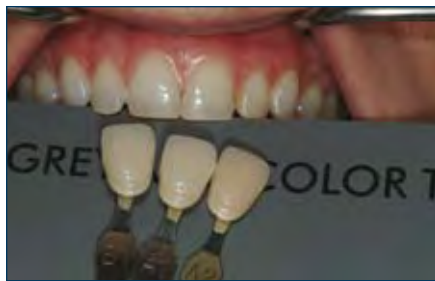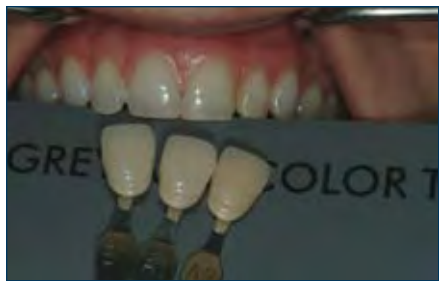**Figure 13** The custom incisal guide table assures duplication of established lingual contours and incisal guidance.



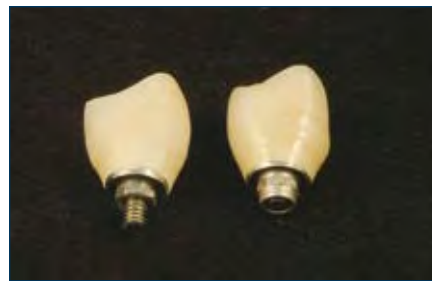**Figure 14** Perpendicular and off angle photographs help the technician interpret surface texture and luster.



**Figure 15** Calibrating both the laboratory and clinician's monitors with a spectrometer is critical for all subsequent color correction.



**Figures 16, 17** Color and brightness are corrected using a batch file in Adobe Photoshop.



**Figure 18** The laboratory technician has used the index to make a slight alteration in buccal contour of the final restoration.

being too deep, or, as in the case of zirconium if placed too shallow or over contoured, a weakened core from grinding (Figure 12). A mounted solid model of the transitional restoration provides a guide for lingual contours and occlusal form utilizing a custom incisal guide table. This is simple to fabricate on the articulator by moving the articulator pin through all of the excursive movements in Triad putty (Figure 13).

The next step is to provide photographs of all the critical views of the transitional restorations. Frontal and lateral views of the close up smile, in addition to a full face frontal photograph help detect subtle contour discrepancies that can be corrected in the final restorations. Perpendicular and off angle photographs help the technician interpret surface texture and luster (Figure 14).

Essential to this step, and one that made the biggest difference in this author's laboratory experience, is color correction of the digital photographs and accurate color viewing. The first step is color correction of the computer monitor of both the dentist and the dental laboratory. The videos cards powering monitors vary for each manufacturer. This is comparable to seeing a different color and intensity on TV screens, as one would see in a TV store. Using a color spectrometer, such as Eye-1 by Greytag McBeth, monitors are

calibrated so that no matter where viewed, the colors and brightness will be nearly the same (Figure 15).

The next step is calibrating the information from the camera as interpreted by the computer. The majority of cameras shoot in RGB formats. These formats are narrower than the true visible light spectrum. Each camera's computer will vary in how the sensors interpret the color out of the range of the RGB spectrum. By shooting photographs of the shade tab in the clinical situation against a neutral grey card, the color can be standardized using a color aware program, such as Adobe Photoshop, to produce a color accurate image for the dental laboratory (Figures 16, 17). Once the color information from the camera has been standardized, the information is stored in a batch file in Adobe Photoshop. The clinical photographs from the day or week can be easily corrected (with a few mouse clicks) from this initial calibration process to convert the images for the dental laboratory.

Many variables can affect the quality of the image, such as ambient light, battery power, subject distance, etc., but when the photographs are recorded in the dental operatory, these variations are tolerable for the accuracy of this process. The details of the above color correction process are too

complex to cover in an article of this length, but taking courses in digital photography and using dental educational DVDs on color management will make this a valuable investment in practice improvement. Other techniques are slightly more sensitive, but would require color correcting each individual image and/or manually capturing each image. Commercial computerized color matching processes are available, that studies have shown increased accuracy in selecting base shade. Digital images are still key to allowing the technician to use one's artistic ability in matching the nuances of shade and translucency. As always, if the laboratory is good at one process or technique, use the one in which they are the most proficient.

Another useful aid that may be preferred by the laboratory is printed color corrected photographs that can be very helpful for critical anterior incisor regions. This also requires calibration of the printer and an additional time commitment to get each case ready for the laboratory.

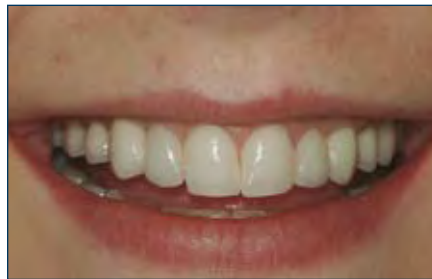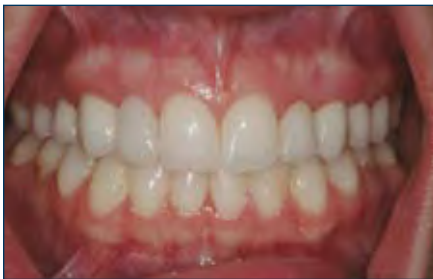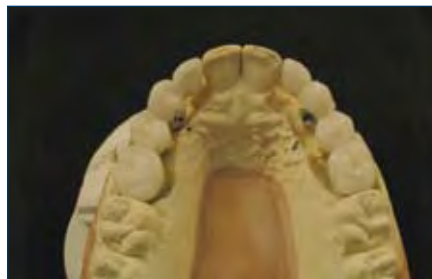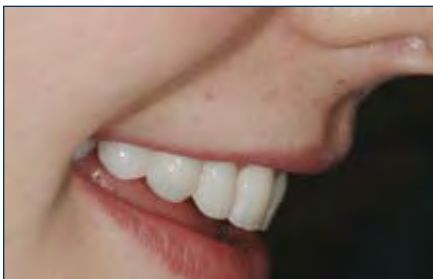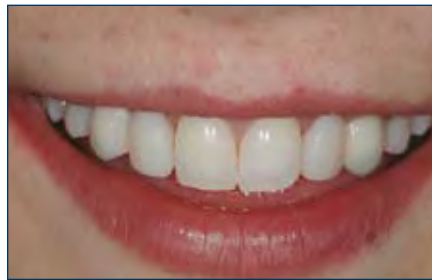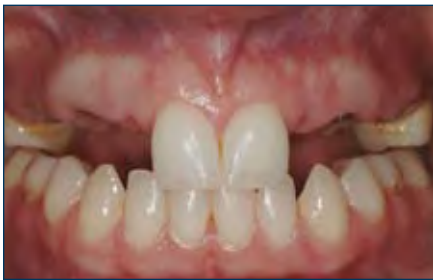The last important step is putting all the images into a PowerPoint presentation. In the process of making the PowerPoint presentation and reviewing the photographs, the dentist will frequently see minor contour discrepancies in the transitional restorations that can be pointed out to the laboratory for

improvement of the final restoration. Specific explanations on how to use the indexes and guides avoid any of these carefully recorded steps being overlooked. Figure 18 demonstrates the similarity of the transitional and final restorations, with a minor requested alteration in buccal contour, after the author evaluated the transitional photographs.

Figures 19-25 show the results of close duplication of transitional restorations and guides in this complex case. This 19 year old female was congenitally missing permanent maxillary laterals, canines, and first and second bicuspids bilaterally. Orthodontics retained a primary molar tooth size in the

second bicuspid site. The case is restored using tissue level implants and treated with single cementable restorations in the primary molar and first bicuspid sites and a cantilever from the canines to restore the lateral incisors. Guides provided or fabricated by the laboratory included separate tissue analogues, gingival mask in the solid model, a putty matrix of the transitional model verifying incisal length, and photographs of transitional restorations. Detailed explanations in the PowerPoint are key to following all of the guides. After lengthy verification of fit, contours, shade, etc., adjustment of one contact was all that was required to seat this case.

Most of the above techniques are quite simple to implement into one's daily routine. Color correction is more of a commitment to the digital process. In today's economic world, there is no better time to make these commitments and elevate your practice's level of care.



**Figures 19-25** In this complex case the laboratory closely followed provided indexes and guides to produce a final result requiring minimal alterations and adjustments.

## References

1. Spear FM, Kokich VG, Mathews DP. **Interdisciplinary management of anterior dental esthetics.** *JADA* 2006;Feb:137:160-169.
2. Kokich VO, Kiyak HA, Shapiro PA. **Comparing the perception of dentists and lay people to altered dental esthetics.** *Journal of Esthetic Dentistry* 1999;11:311-24.
3. Preston JD. **The Golden Proportion Revisited.** *J Esthetic Dent* 1993; 5:247-51.
4. Chu SJ. **Range and mean distribution frequency of individual tooth width of the maxillary anterior dentition.** *Pract Proced Aesthet Dent* 2007; 19:209-15.
5. Chu SJ, Hochman HM, Fletcher P. **A biometric approach to crown lengthening: Part II-Interdental Considerations.** *Pract Proced Aesthet Dent* 2008;20: 529-536.
6. Kokich VO, Kokich VG, Kiyak HA. **Perceptions of dental professionals and laypersons to altered dental esthetics: Asymmetric and symmetric situations.** *American Journal of Orthodontics and Dentofacial Orthopedics* 2006;8:141-151.
7. Frank Spear, DDS, MSD. **Color Managing Digital Photography For the Dental Office.** *Spear Institute of Advanced Dental Education, DVD 2009.*
8. Frank Spear, DDS, MSD. **Making Good Images Perfect With Adobe Photoshop.** *Spear Institute of Advanced Dental Education, DVD 2009.*
9. Frank Spear, DDS, MSD. **Choosing and Setting a Digital Camera.** *Spear Institute of Advanced Dental Education, DVD 2009.*

Due to the fact that this issue of Implant Realities is a “Congress Issue”, a literature review has not been included . . .

## **Do not despair!**

### **The Literature Review section of Implant Realities will return with our 2010 Spring issue.**

Please send to me any articles/monographs/textbooks/etc. which you have published, or have had accepted for publication since September 1, 2008. As always, please include the title and reference of the publication, and a one paragraph description of the content.

- Paul Fugazzotto, DDS



# Article Submission Information

*Implant Realities* articles can be sent via mail or email, depending upon the size of the article. Information and submission deadlines are included below.

**Via Email:**  
progressiveperio@aol.com

**CD-ROM Via Mail:**  
Dr. Paul Fugazzotto  
25 High Street, Suite 103  
Milton, MA 02186

**Target Calendar for 2010 Publications:**

January 2010  
June 2010

Submission Deadline for Spring 2010 Publication  
Submission Deadline for Fall 2010 Publication

## Submission Requirements:

### Submission Format

All articles should be accompanied by the following:

- *Implant Realities* submission form
- Brief biographies for all authors
- Article format: Word document
- Digital photos (.eps or .tif and 300 dpi or higher resolution) of all authors
- All photos must be accompanied by full sentence captions

### Article Length

Articles can be between 3 to 15 pages dependent upon the subject covered.

### Photos

Digital pictures will be accepted with articles and should be noted in text as (see photo 1) so that an accurate placement can be easily identified. Digital photos must be in .eps or .tif format and at 300 dpi or higher resolution. The maximum number of pictures should be 20. Figure captions must accompany all photos.

### Topics

*Implant Realities* will be divided into seven categories: Editorials, Surgical, Restorative, Laboratory, Team Dentistry, Treatment Planning, and Literature Reviews.

### Article Review

All articles will be reviewed before publication for grammatical and spelling errors. Article content or conclusions will not be altered during this process.

### Article Status

The primary author will be notified via e-mail upon article acceptance, decline or request for rewrite after the review process. *Implant Realities* reserves the right to decline an article for any reason. If an article is declined the author/s can ask for an evaluation, at their discretion.

### Final Publication

All articles and digital photos will be formatted in accordance with *Implant Realities* guidelines.

# Implant Realities Submission Form

Date of Submission:

Name/Main Author:

Title:

University/School:

Address:

City:

State:

Zip:

Phone:

Fax:

\*e-mail:

*\* Please note communication regarding submission status and questions regarding articles will be sent via e-mail.*

**Additional Authors:**

**Article Category:**

Editorial

Restorative

Treatment Planning

Surgical

Team Dentistry

Literature Review

Laboratory

**Brief Description:**

**How to Submit:**

**Via e-mail:**  
progressiveperio@aol.com

**CD-ROM Via Mail:**  
Dr. Paul Fugazzotto  
25 High Street, Suite 103  
Milton, MA 02186

